SIEMENS

DynaCT

CT-ähnliche Bildgebung am C-Bogensystem

Technologie und klinischer Einsatz

Dr. Martin Ostermeier

Siemens Medical Solutions
Forchheim

Siemens **Medical**
Solutions that help

Oftmals ist 3D Bildgebung <u>während</u> der Intervention wünschenswert

Patiententransport ist die Herausforderung

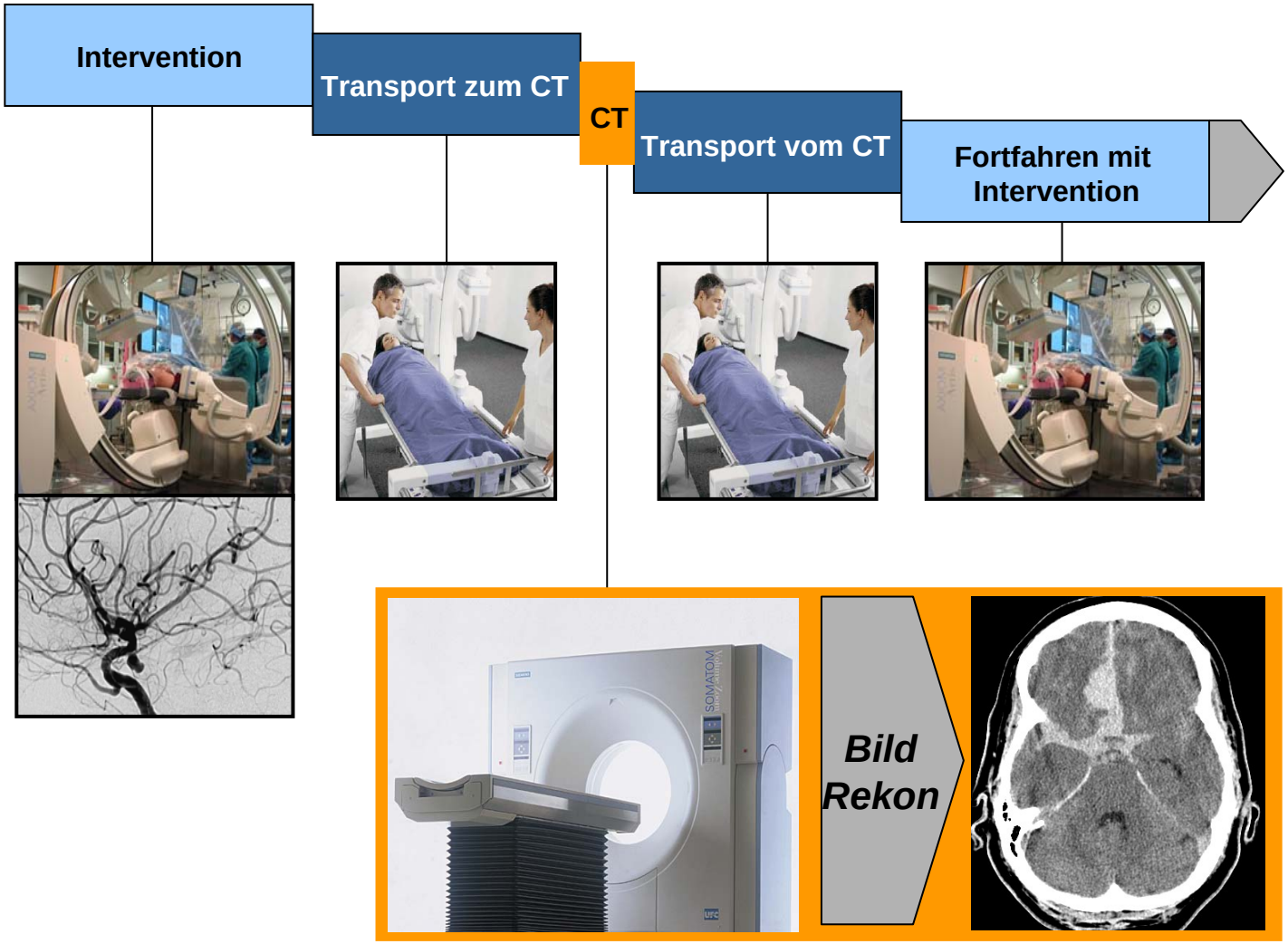

CT-ähnliche Bildgebung am C-Bogensystem mit DynaCT

- deutliche Verbesserungen im klinischen Ablauf
- höhere Patientensicherheit

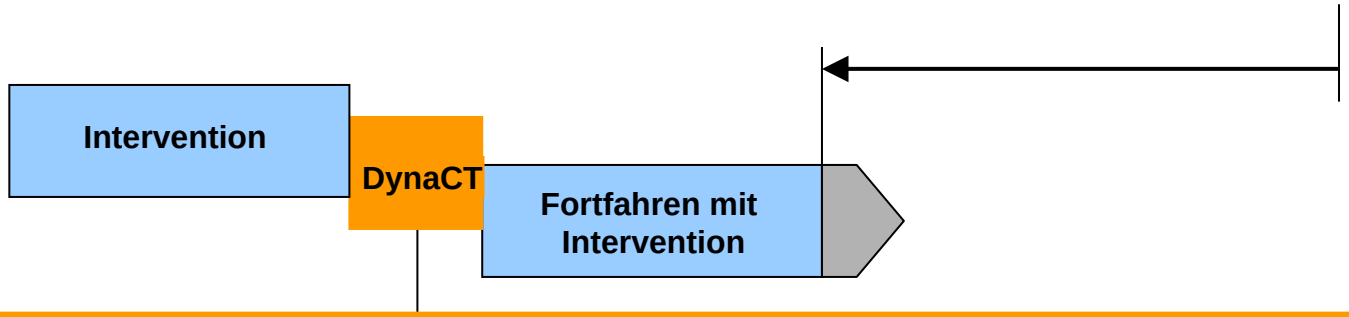

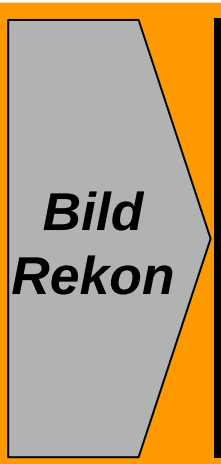

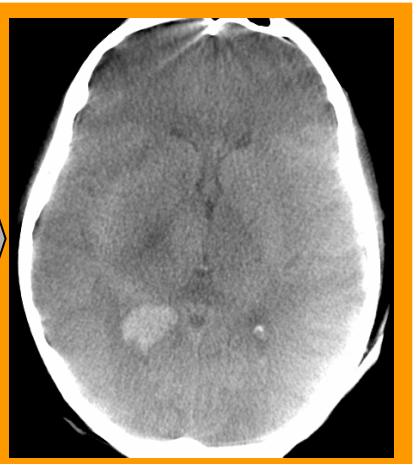

Workflow DynaCT

Rotationsangiographie
- mit 30 (60) Bildern pro Sekunde
- 280 .. 560 Projektionen in (5) .. 10 .. 20 Sek.

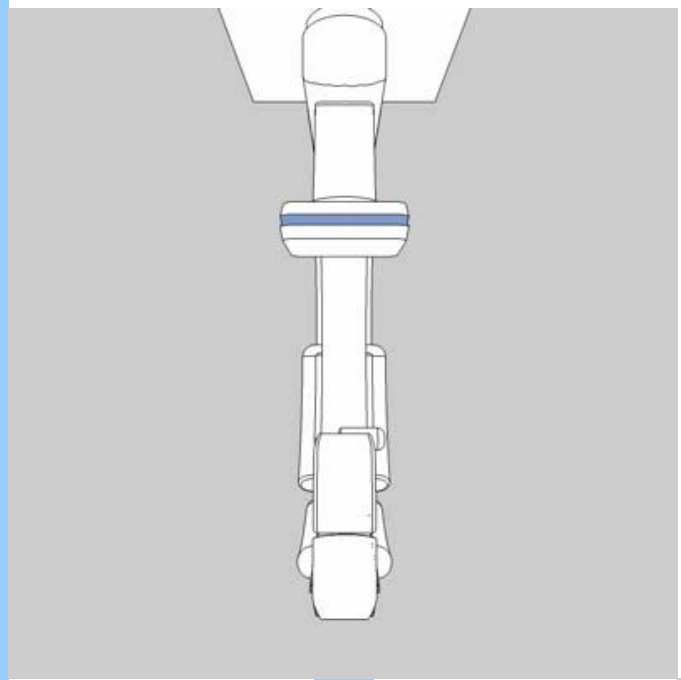

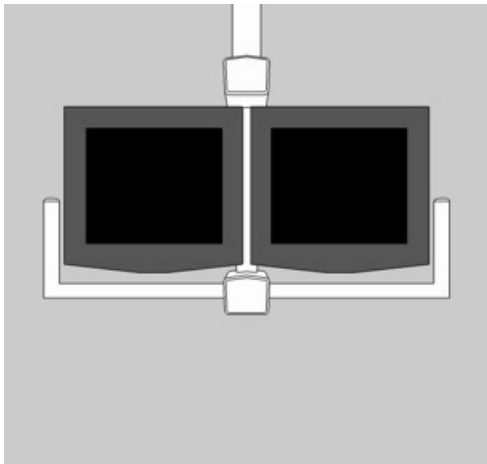

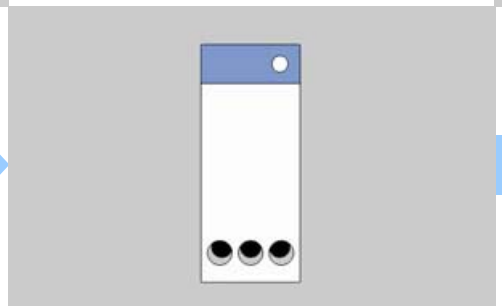

Workflow DynaCT

Rotationsangiographie
- mit 30 (60) Bildern pro Sekunde
- 280 .. 560 Projektionen in (5) .. 10 .. 20 Sek.

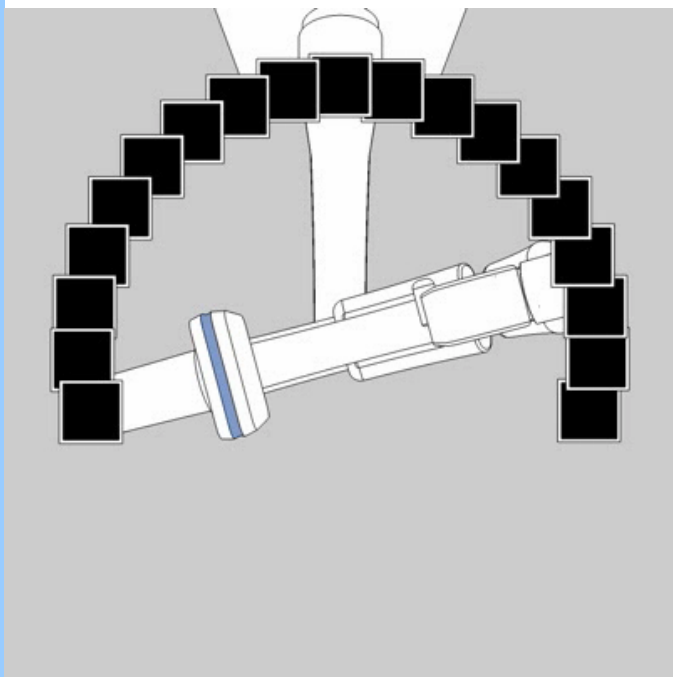

Display am Angiotisch

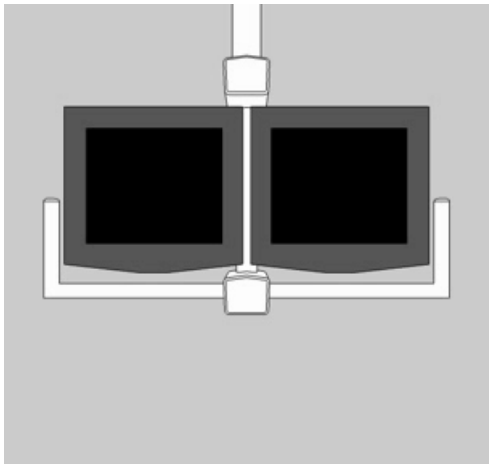

LEONARDO
Workstation
CT Rekonstruktion

Bild-
transfer

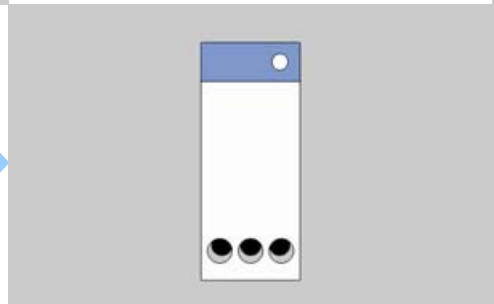

Editing
3D
InSpace
Type
Orient
Table
Ramp Brightness
Ramp Opacity
Brightness
Opacity
Clip
Tools
Measure
X-Ray

Technologie

Flachdetektoren

- **Umwandlung von Röntgenstrahlen in einer einzigen Komponente**
- **Modernste Szintillator Technologie**
  - Cäsiumjodid wandelt Röntgenphotonen in Licht um
  - über 4,7 Millionen Photodioden digitalisieren die Lichtintensität
- **Der FD ist integriert in eine innovative Bildkette**

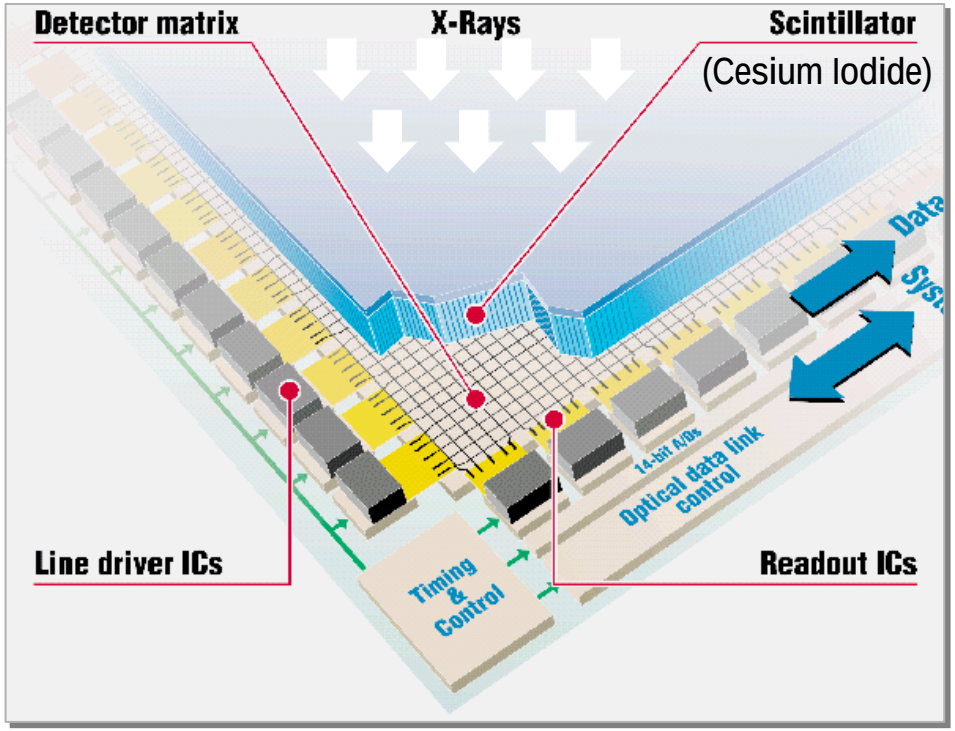

Der neue AXIOM Artis FD erhöht die Sichtbarkeit kleinster Details

- **Hohe Graustufenauflösung (14 bit)**
  - Differenzierung von kleinen Kontrastunterschieden
  - geringere Überstrahlung
  - potentiell keine Notwendigkeit von semitransparenten Filtern
  - 3D-Bildgebung von Niedrigkontrastobjekten
- **Hervorragende Ortsauflösung**
  - 154 µm² Pixelgröße (3,25 Lp/mm)
  - durch die Nadelstruktur des CsJ-Szintillators wird das Licht „geführt“ und dadurch die Streuung minimiert



E-Mikroskopie des CsI Szintillators

Der Flachdetektor liefert homogene Bilder



Bildverstärker



Flachdetektor

Der Flachdetektor bietet die höhere Ortsauflösung





Niedrigkontrast-Auflösung benötigt viele Projektionen

Simulation

Messung

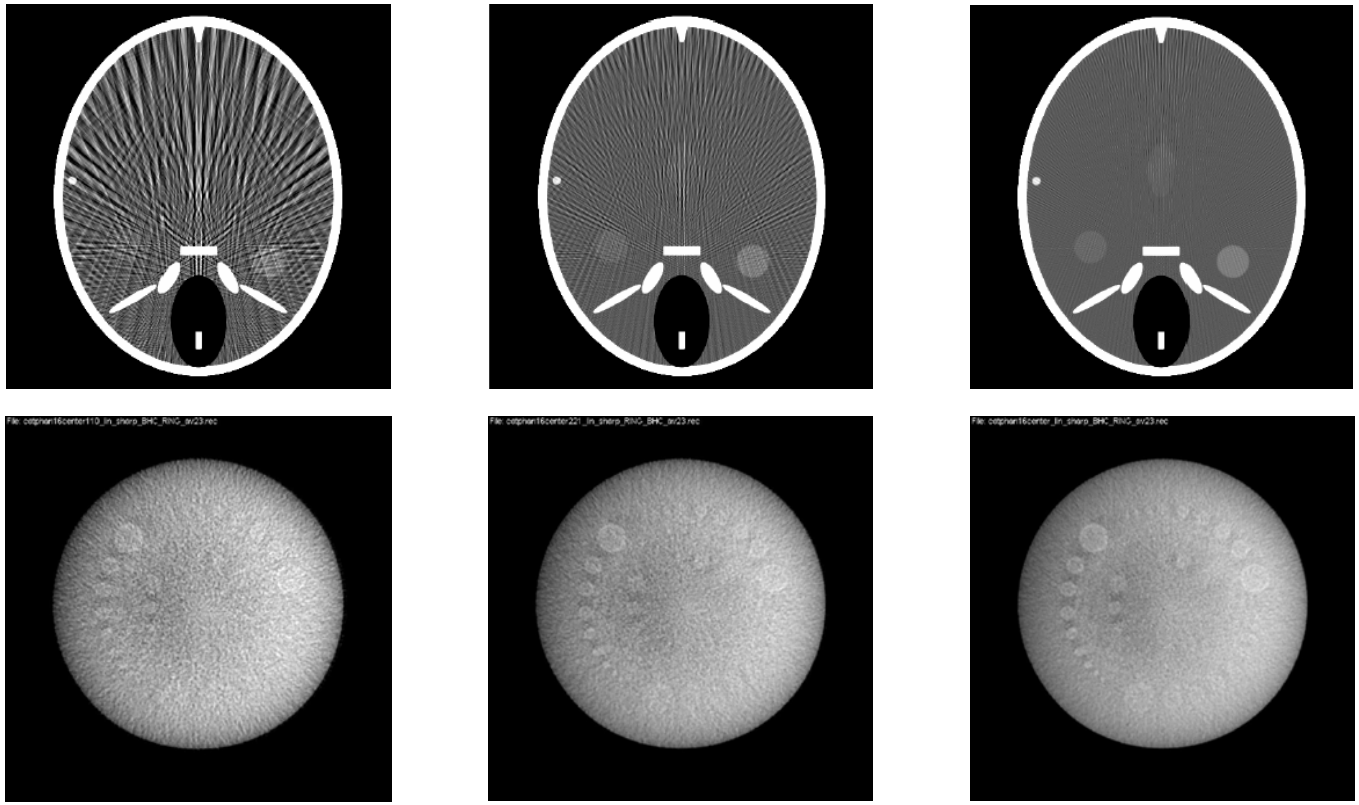

120 Projektionen | 240 Projektionen | 480 Projektionen

Mit AXIOM Artis FD stehen hohe Bildraten zur Verfügung



unkorrigiert



1 Iteration



5 Iterationen

Iterativer Algorithmus für primäre Verteilungsabschätzung

$$P^{(0)} = T_M \quad \text{with} \quad T_M = \frac{J}{J_0}$$ (gemessene Primär- & Streustrahlung)

Streustrahlen-Abschätzung

$$H_W^{(n)} = -W \cdot P^{(n)} \ln P^{(n)}$$ (W = ortsabh. Gewichtung)

$$S^{(n)} = H_W^{(n)} ** G$$ (G = Glättungskern)

Streustrahlen-Korrektur

$$P^{(n+1)} = T_M \frac{P^{(n)}}{P^{(n)} + S^{(n)}}$$

$J_{Streu} = 20 * J_{Primär}$

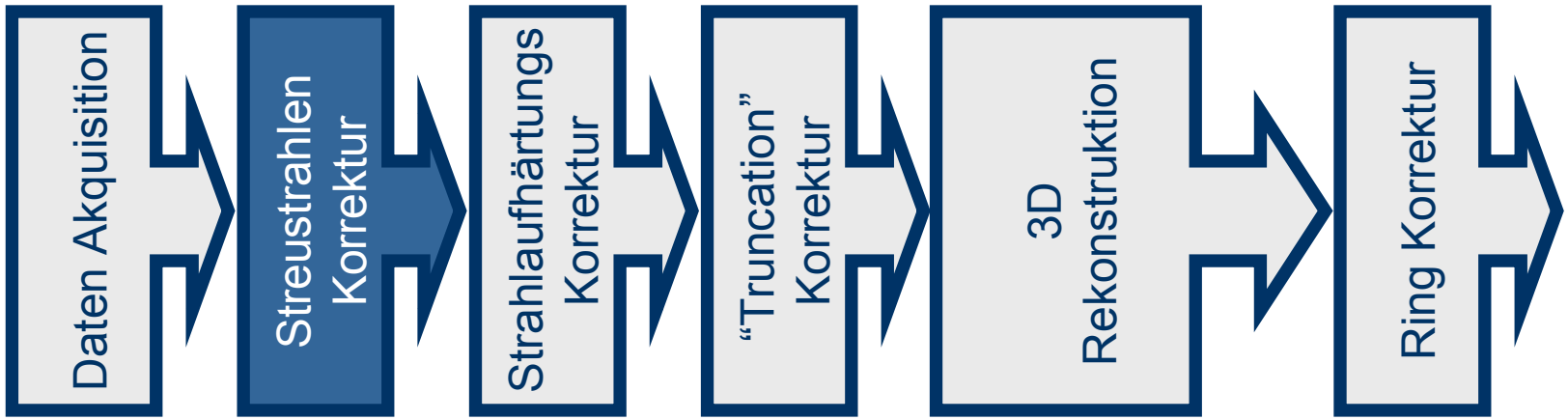

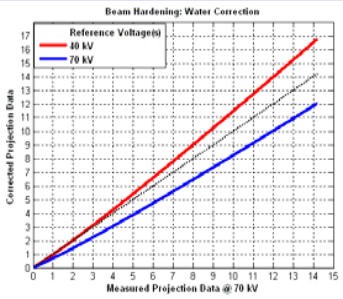

Mapping Kurven

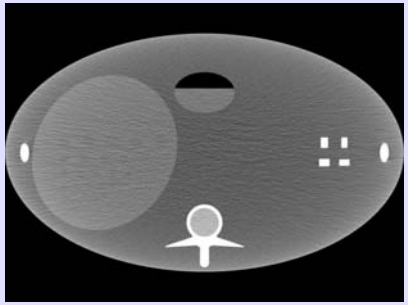

unkorrigiert



korrigiert

Artefakte durch Strahlaufhärtung entstehen durch nichtlineare Absorption polychromatischer Strahlung.
Korrektur durch Umrechnung der gemessenen polychromatischen Werte auf monochromatische Projektionsdaten gleicher Energie (Kompensation der unterschiedlichen Spannungswerte)

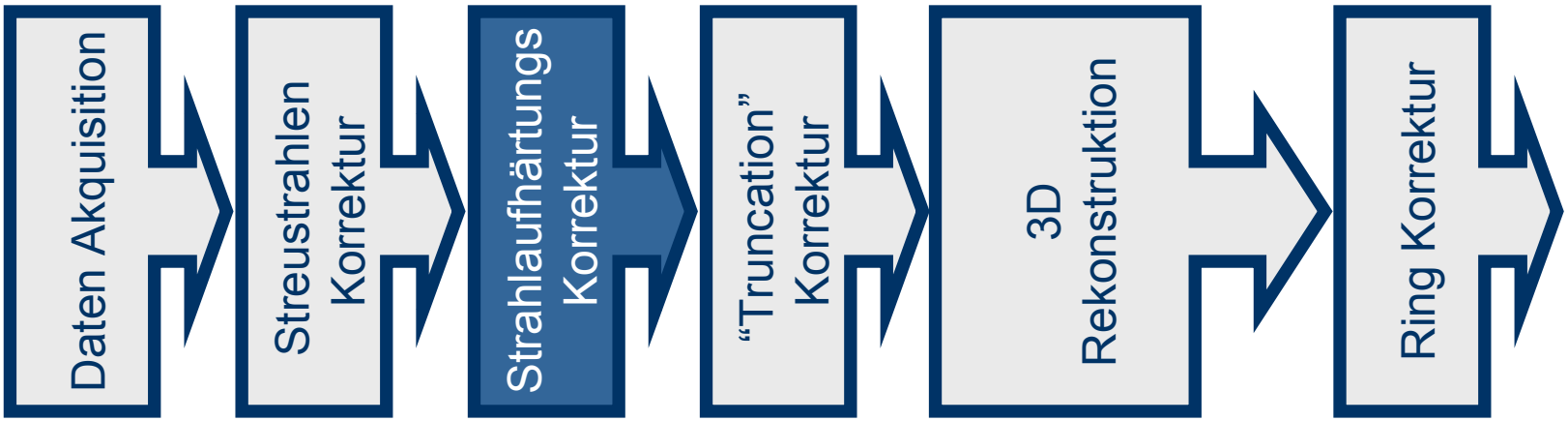

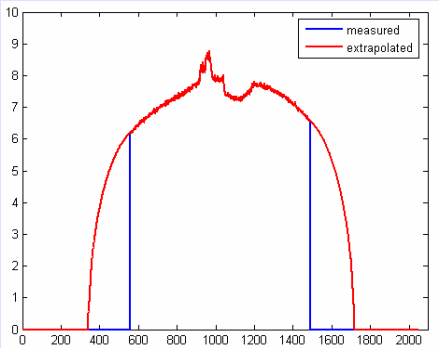

Extrapolation der Dichte



unkorrigiert

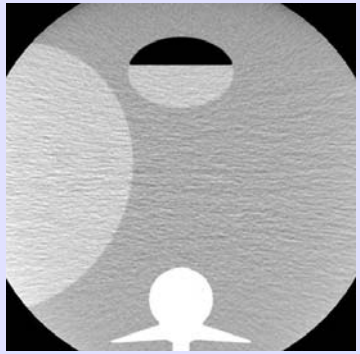

korrigiert

Abgeschnittene Projektionen (“Truncation”) werden extrapoliert. Der Typ der Extrapolation hängt von der Kurvensteigung am Projektionsrand ab.



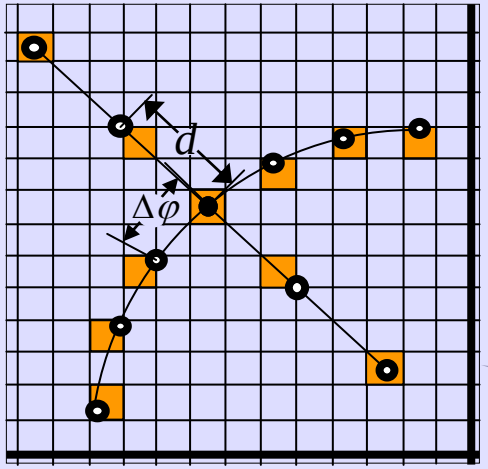

1. Extrahieren des Ring-Bildes
- Einfluss einzelner Pixelwerte
- subtrahieren des radial-median gefilterten Bildes
- kreisförmige Glättung

2. Subtraktion des Ring-Bildes

kartesische Koordinaten !


Eingangsbild

Ring-Bild

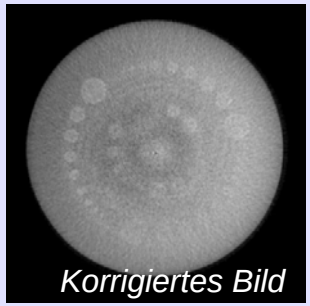
Korrigiertes Bild

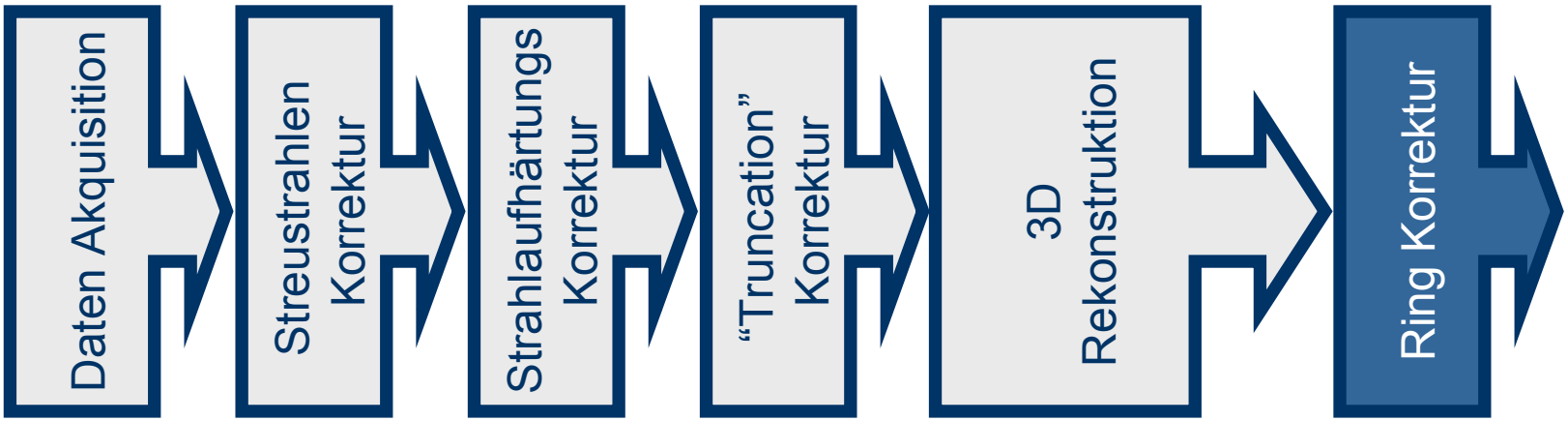

Was ist entscheidend für DynaCT ?

- **FD Technologie**
  - großer Detektor
    - keine oder kompensierbare Abschneidung (“Truncation”)
  - 14 BIT Grauskalentiefe
  - homogene Bildgebung über den gesamten Detektor

- **Leistungsfähiges Bildsystem**
  - hohe Bildfrequenz
  - leistungsfähige Rekonstruktionsalgorithmen

- **CT–Grundlagen, angewendet auf FD**

Wo liegen die Vorteile von DynaCT ?

- Zusätzliche CT-Information mit Weichteilkontrast (10 mm / 10 HU)
- Mögliche Vermeidung von Patiententransfers zu CT / MR
- Optimale Integration von 3D Bildgebung in den interventionellen Workflow

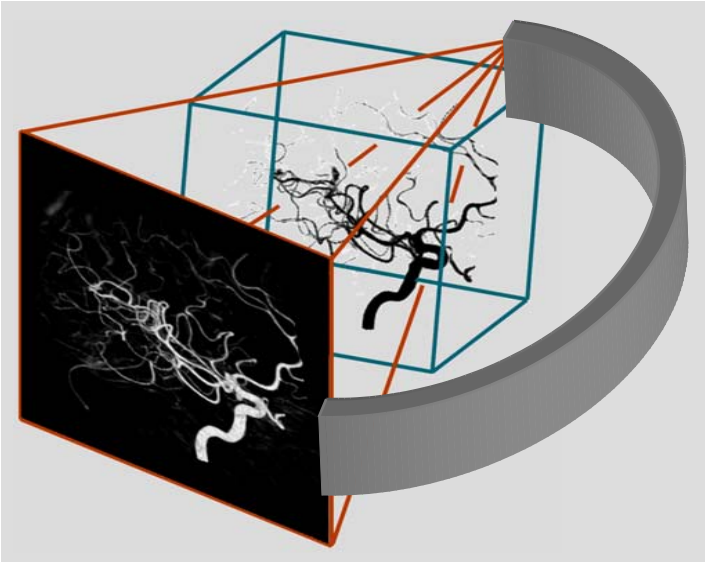

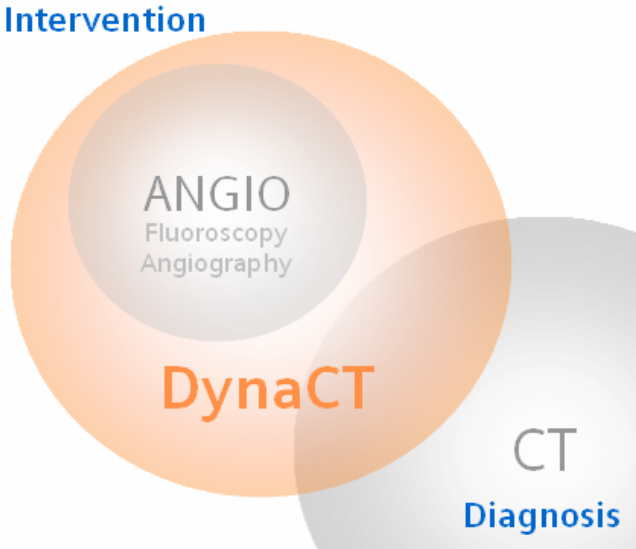

Was sind die Unterschiede zwischen DynaCT und Mehrschicht-CT ?

DynaCT	Mehrschicht CT
interventionell	diagnostisch
Volumenakquisition	Spiralakquisition
960 Zeilen	64 Zeilen
200° in 10-20 s	360° in 0.37 s
10 HU	1 HU

Historie von DynaCT

Enge Kooperationen mit wissenschaftlichen und klinischen Partnern

Physik – Phantomstudien – Tierlabor – Klinische Validierung

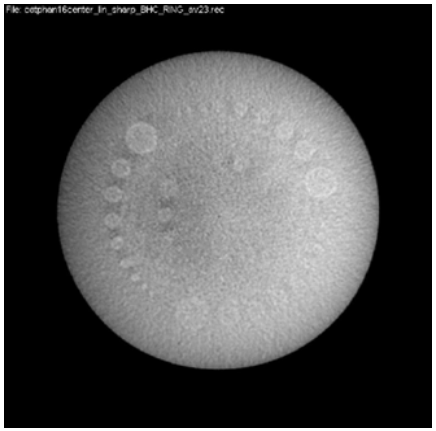

Institut für Medizinische Physik
Erlangen, Prof. Kalender

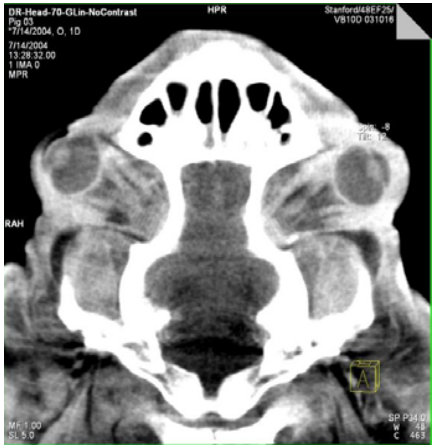

Tierlabor der Stanford Universität
USA, Prof. Glazer

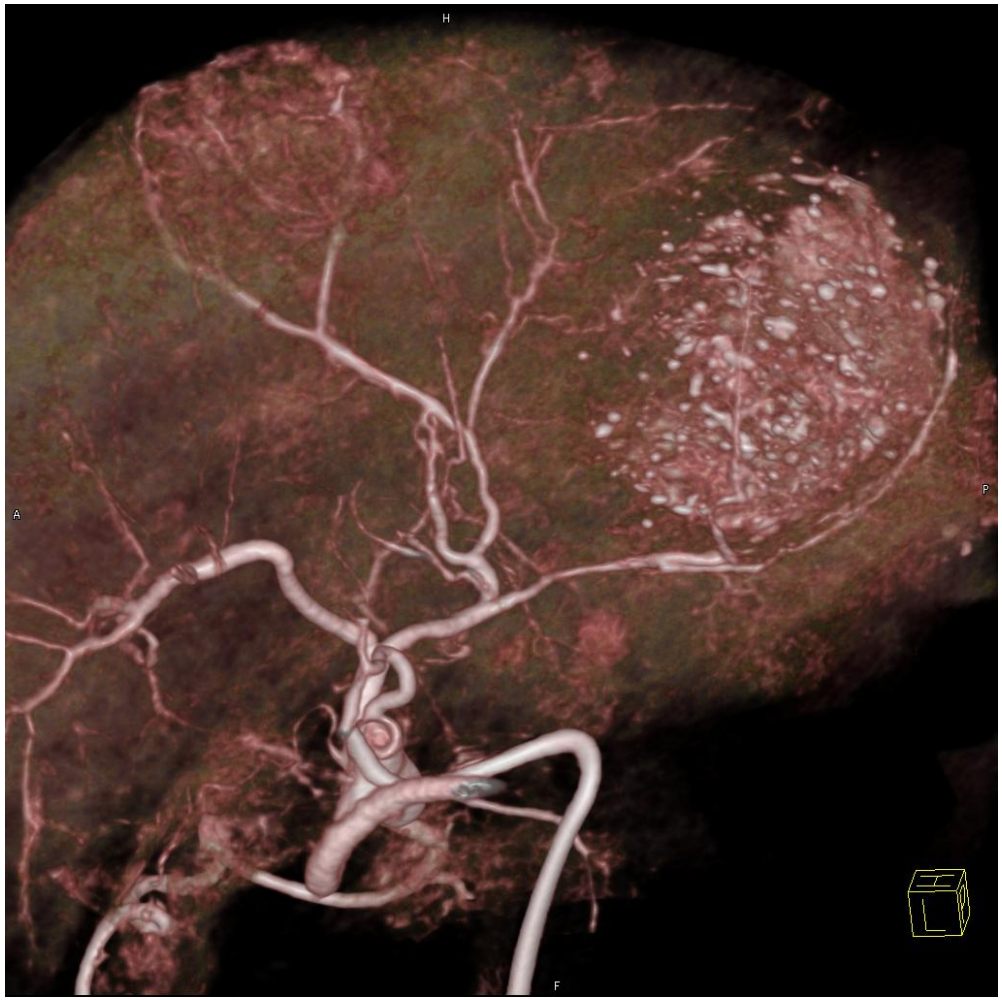

Chiba Cancer Center
Japan, Dr. Takano

1. Schritt:
Labor

Ausgezeichnete Niedrigkontrast-BQ mit DynaCT

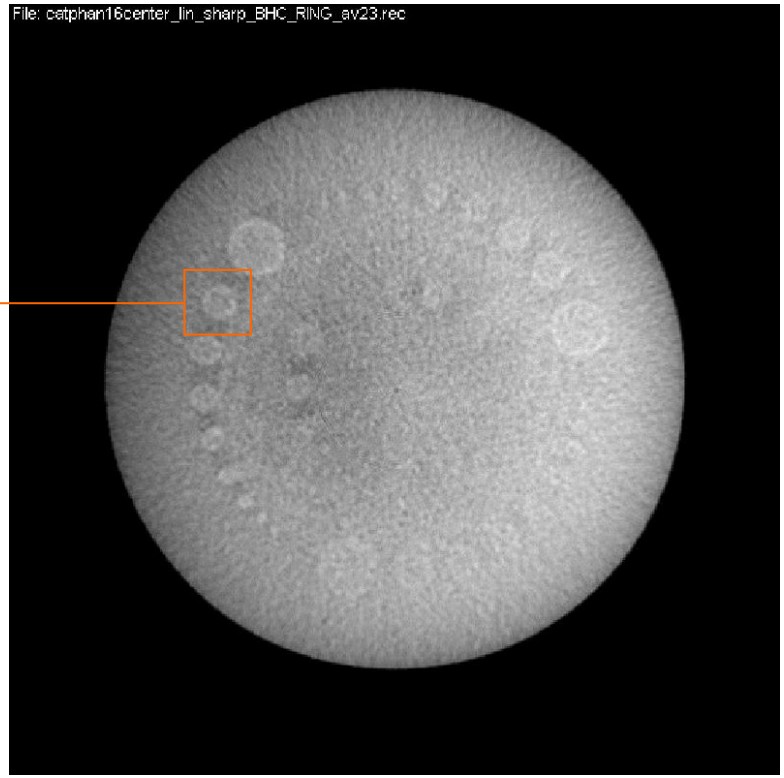

DynaCT bietet NK-Auflösung von 10 mm @ 10 HU

DynaCT

AXIOM Lab @Uni. Erlangen (Human Bone sample)

Scan Parameter: 81 kV, 3.6 µGy/Projektion, 398 Projektionen
Fokus = 0.4 mm, R_{FD} = 1200 mm

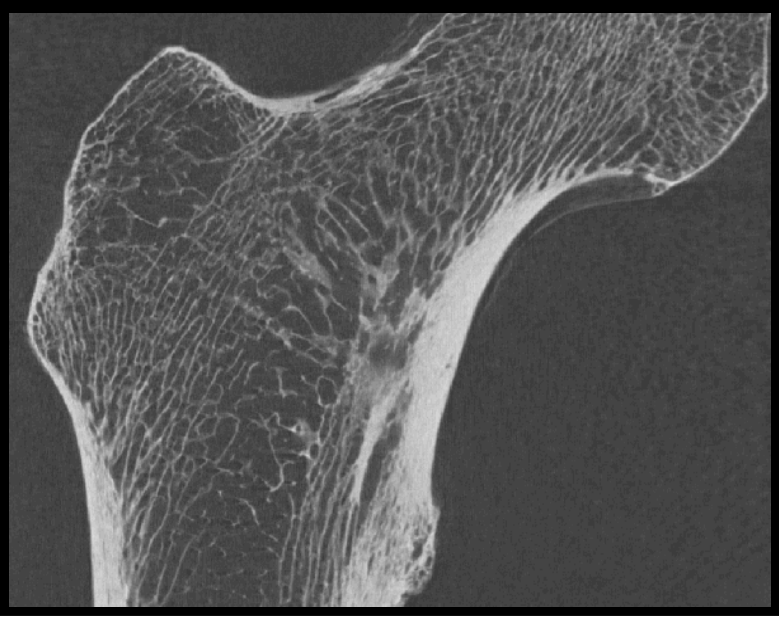

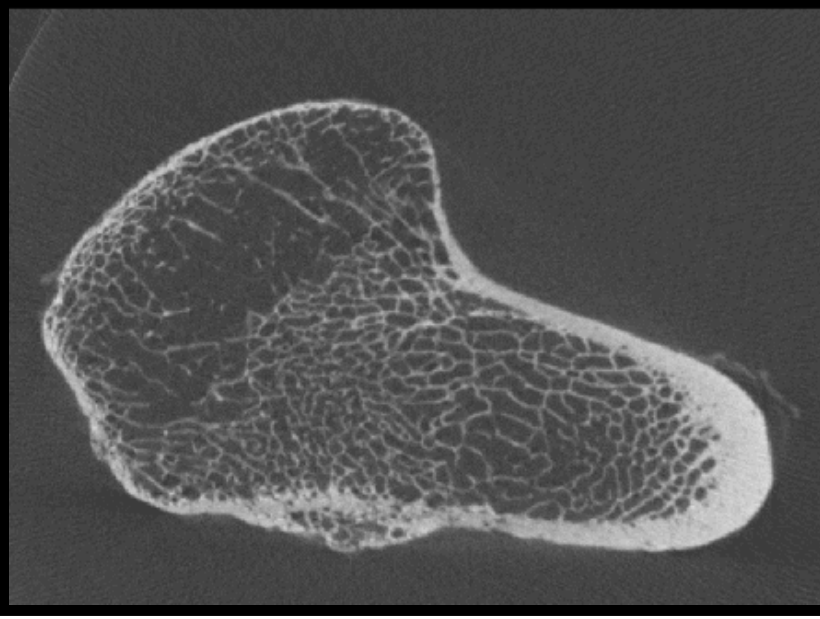

DynaCT Dosis/CTDI

CT dose index plastic cylinder

(Durchmesser 160 mm)

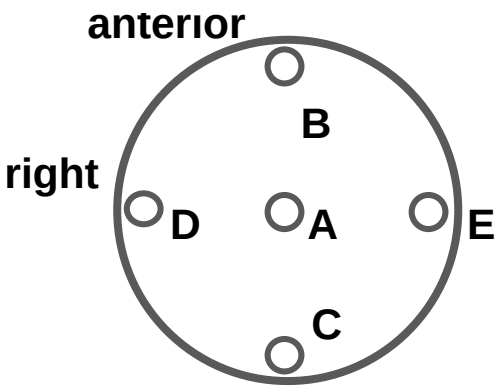

DynaCT:

Catphan: 70 kV, 3.15 mAs/Projektion,
273 Projektionen → 863 mA und 22 mGy

CT:

Typische Dosis bei kranialem CT : 20 - 50 mGy

2. Schritt:
Tierlabor

AXIOM Lab @ Stanford, USA

Artis dTA (5.0mm slice)

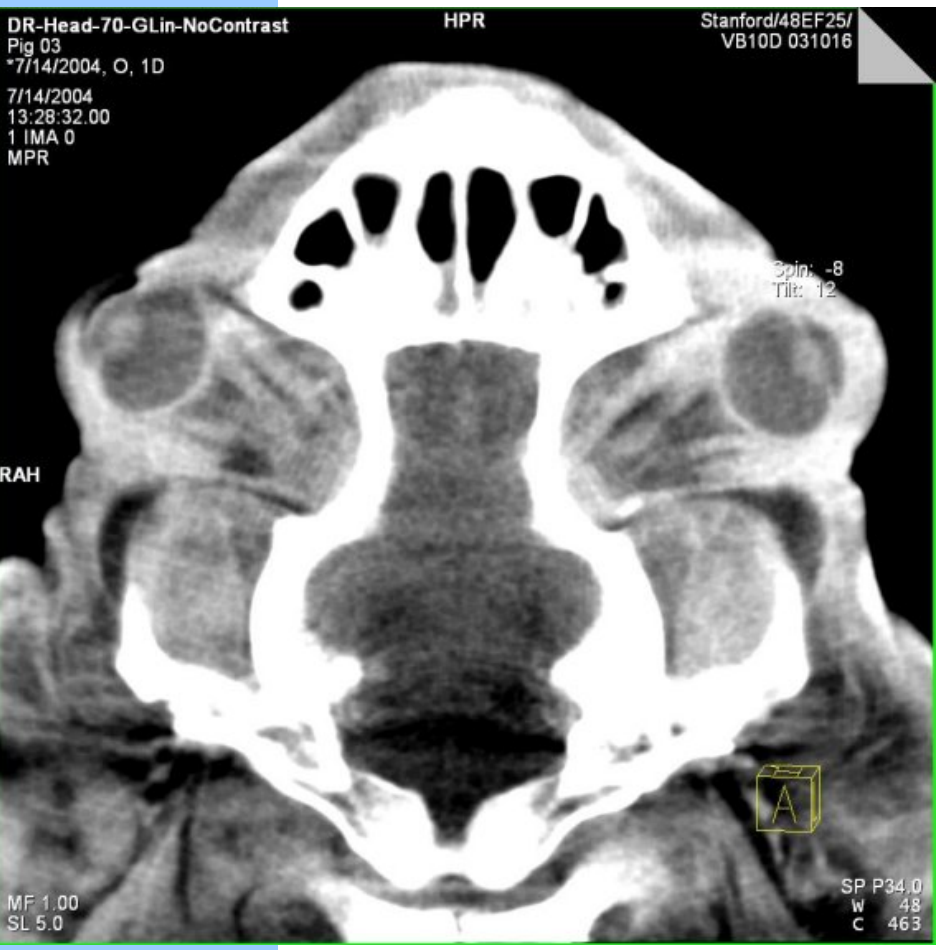

Sensation 16 (5.0mm slice)

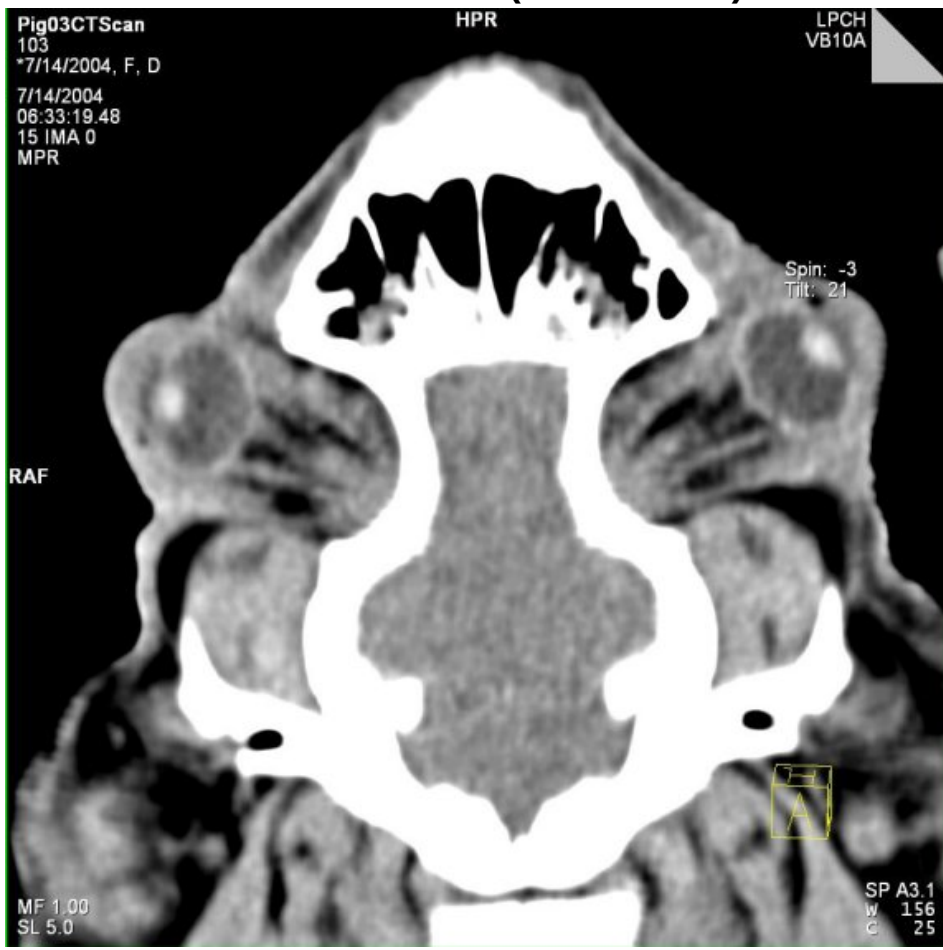

3. Schritt:
Klinische Anwendung

Klinische Ergebnisse mit DynaCT

Methodist Hospital – Houston, USA

Dr. C. Strother

Ein 13 Jahre alter Junge bekam heftige Kopfschmerzen beim Basketballspielen und kollabierte.

Am “Texas Childrens Hospital” wurde mittels CT ein AVM diagnostiziert.

Der Patient wurde zur weiteren Behandlung ins “Methodist Hospital” gebracht.

Am nächsten Tag konnte mit DynaCT gezeigt werden, dass das AVM über Nacht nicht gewachsen ist.

Das AVM wurde mittels Strahlentherapie behandelt.

Patient Applications Edit Film Image Options Help

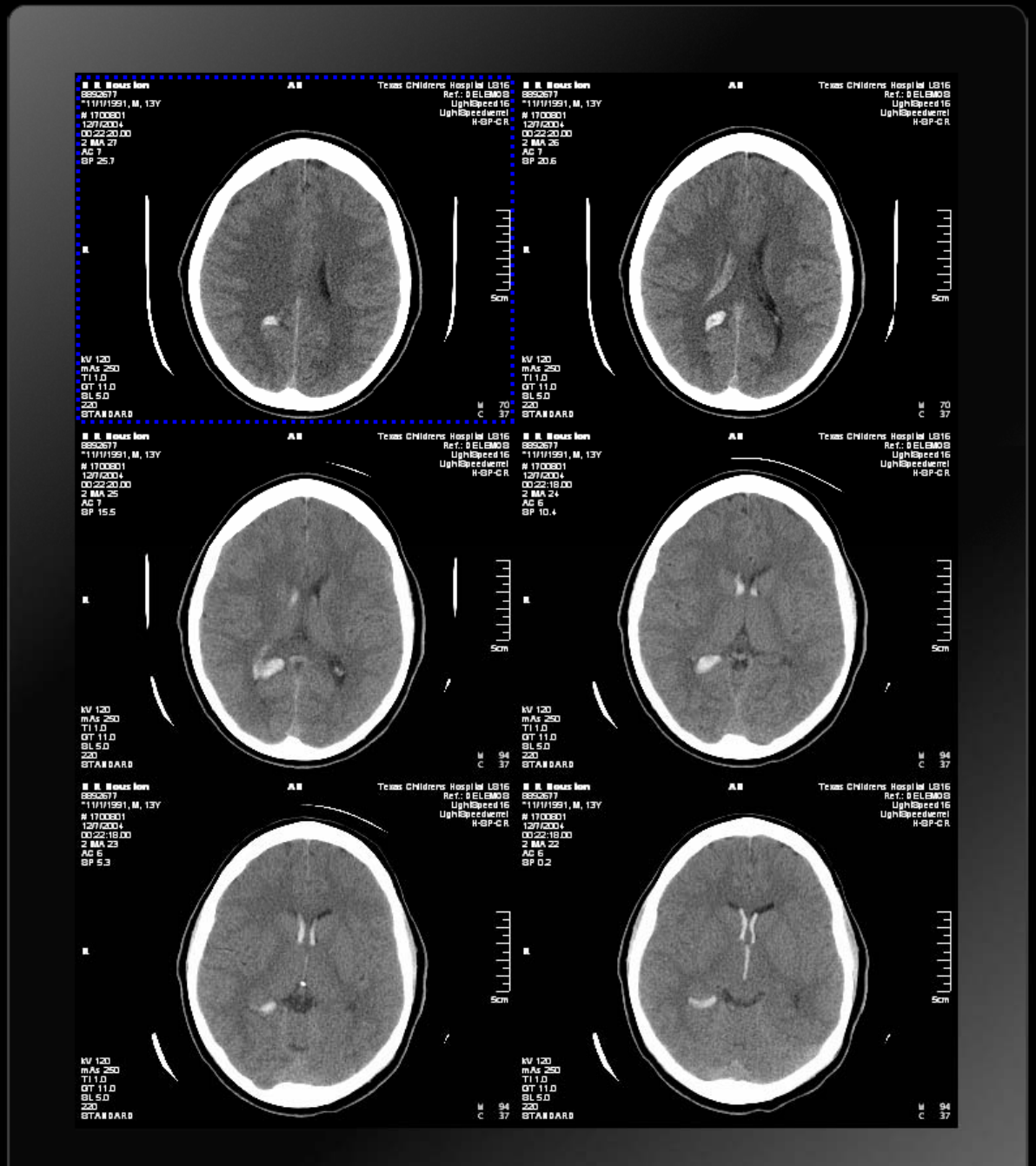

1st day:

CT



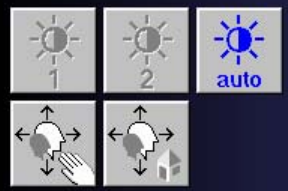

Filming

3D

Angio

Patient Applications Edit Film Image Options Help

1 of 2

2nd day:

DynaCT

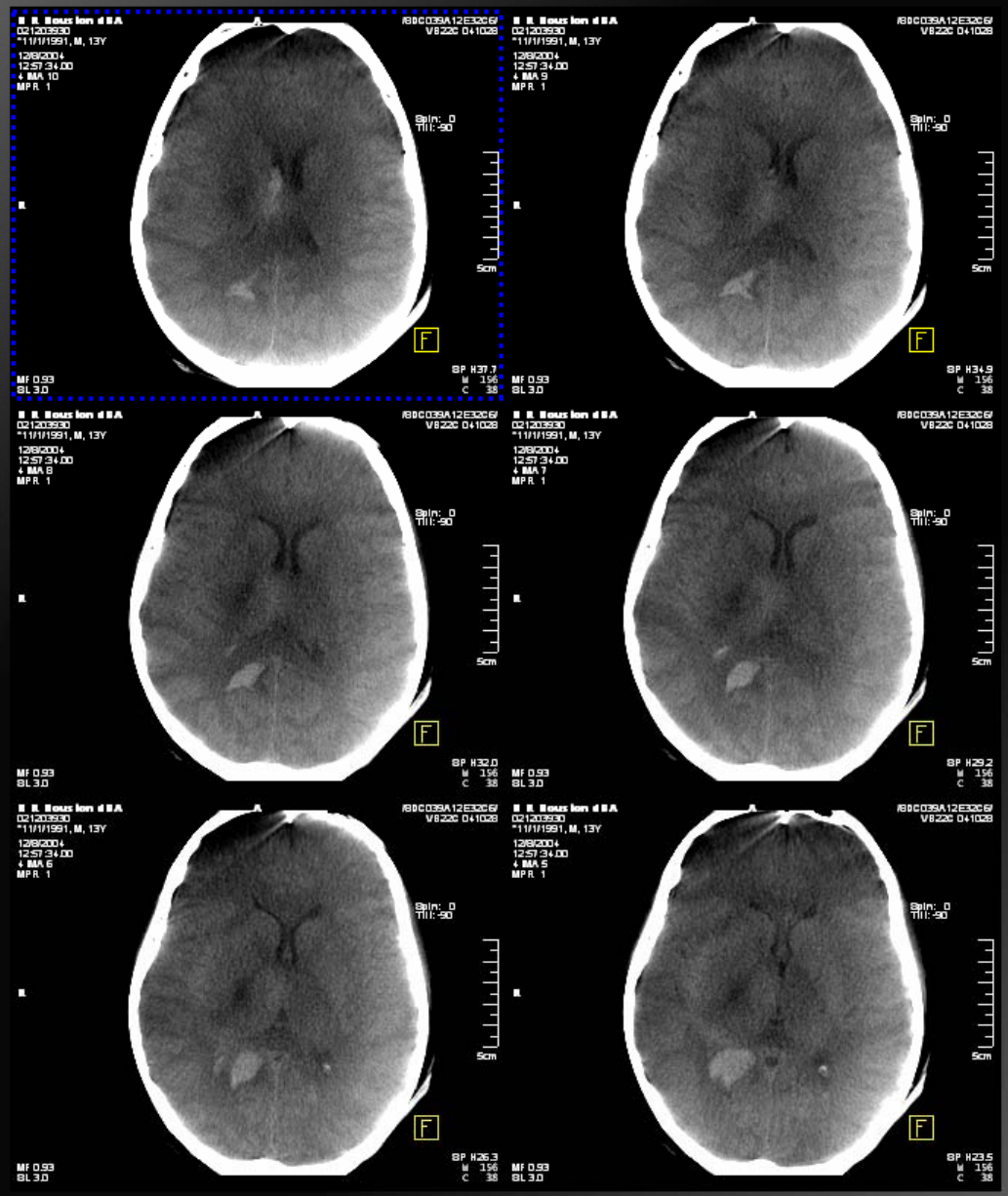

1 Copies

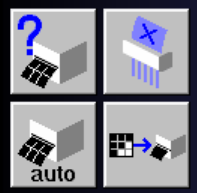



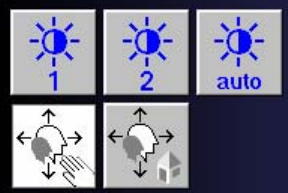

Filming

3D

Angio

Klinische Ergebnisse mit DynaCT

Chiba Cancer Center, Japan

Dr. H. Takano

- **Interventionelle Tumorbehandlung**
- **Angiosystem & Sliding Gantry CT**
- **Bisher:**
  - Intervention auf Angio
  - Kontrolle auf CT
- **Heute:**
  - Angio mit DynaCT

Comparison:
16MDCT and DynaCT

Fig.1 MPR (sagital) image

"Although the low-contrast resolution of DynaCT is not equal to that of conventional CT, it is adequate for interventional application. "

Fig.2 VR (Left-lateral) image

"DynaCT has smaller voxel size and thus higher spatial resolution than MSCT. In addition,the voxels have a perfect cubic shape, which is a great advantage over MSCT. The thickness of the MSCT slices has negative effect on its voxel shape."

Fig.1

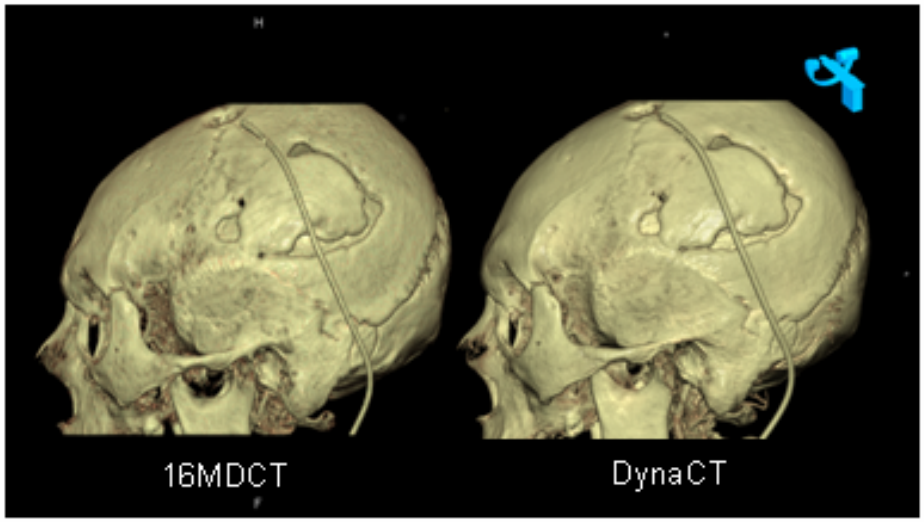

Fig.2

Metastatic brain tumor; **Neuro navigation**

DynaCT; DR10s

Fig.1 MPR (sagital, oblique)

"Size and shape of enhanced tumor, and the other soft tissue is shown."

Fig.2 VR(Volume Rendering)

"Spatial relationship between tumor and vessel is clear. You can differentiate artery and vein on the image. This kind of information is useful for neuro navigation or vessel mapping. "

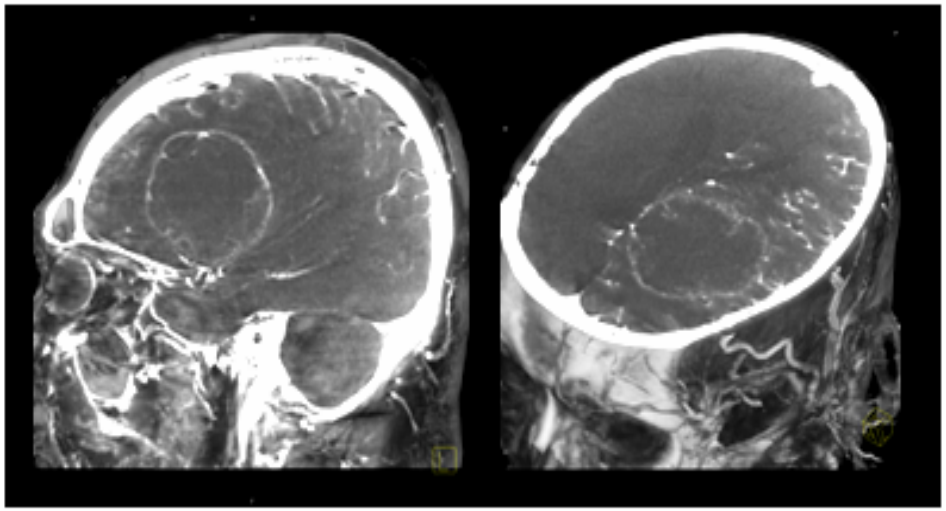

Fig.1

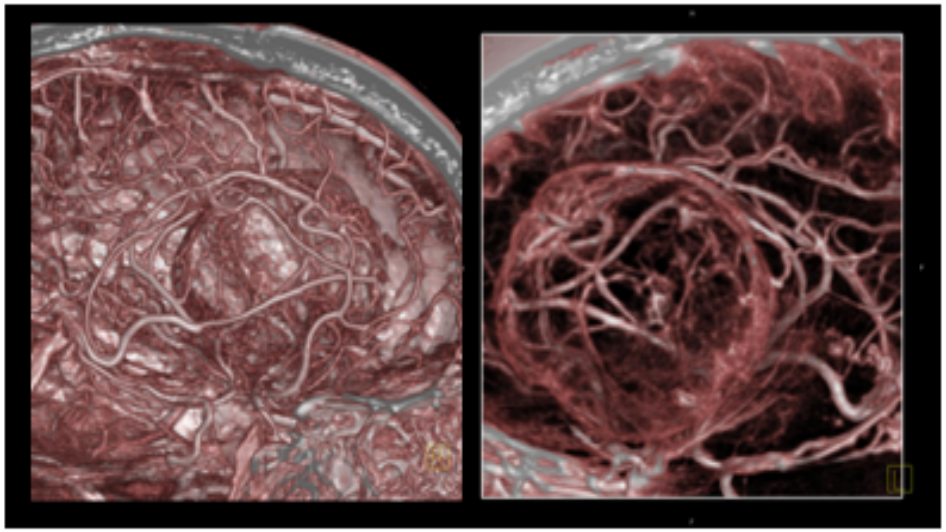

Fig.2

RCC Scapula metastasis;
Pre-operative Embolization

DynaCT; DR10s

Fig.1 MPR (frontal, right-lateral) pre-embolization

Fig.2 VR images pre-embolization

Fig.3 MPR (coronal, Right-lateral) Post-embolization

"It was very difficult on fluoro-scopy to determine whether the whole tumor was embolized. DynaCT convinced us about the entire embolization of the tumor. Ortho surgeons completed the total resection only with autologous blood transfusion. "

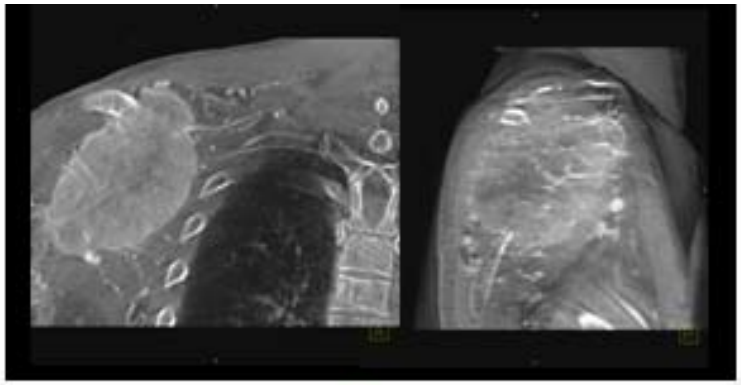

Fig.1

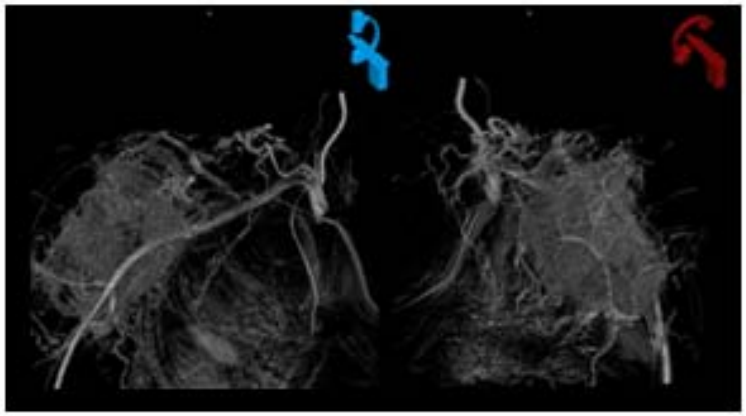

Fig.2

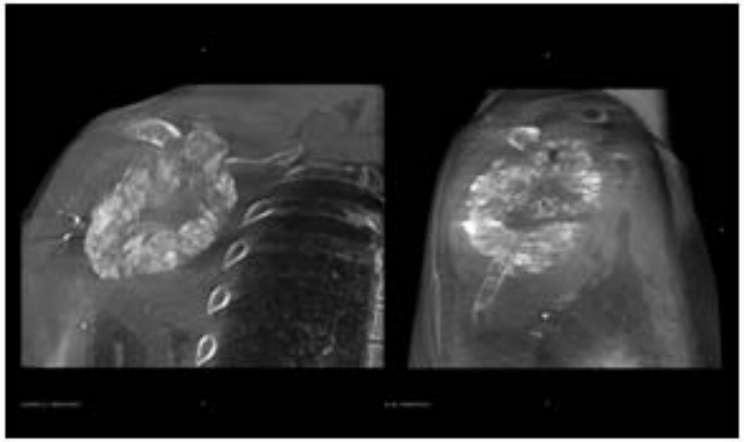

Fig.3

Comparison:
Original DSA and DynaCT

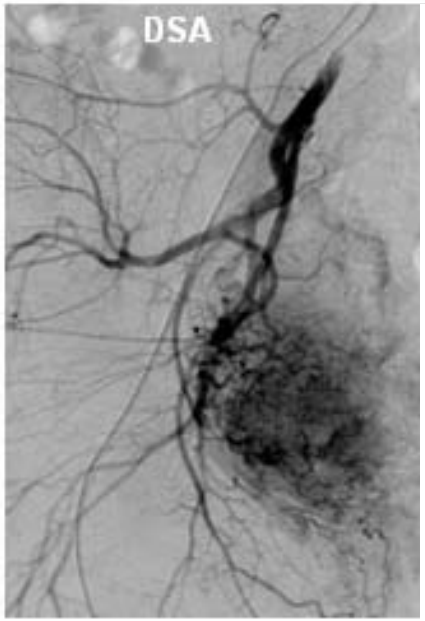

DynaCT; DR/DSA 10s
Case: Ovarian tumor recurrence

Fig.1 DSA image

Fig.2 Left: DynaCT, VR
Right: DynaCT,
Dual volume VR (DSA+DR)

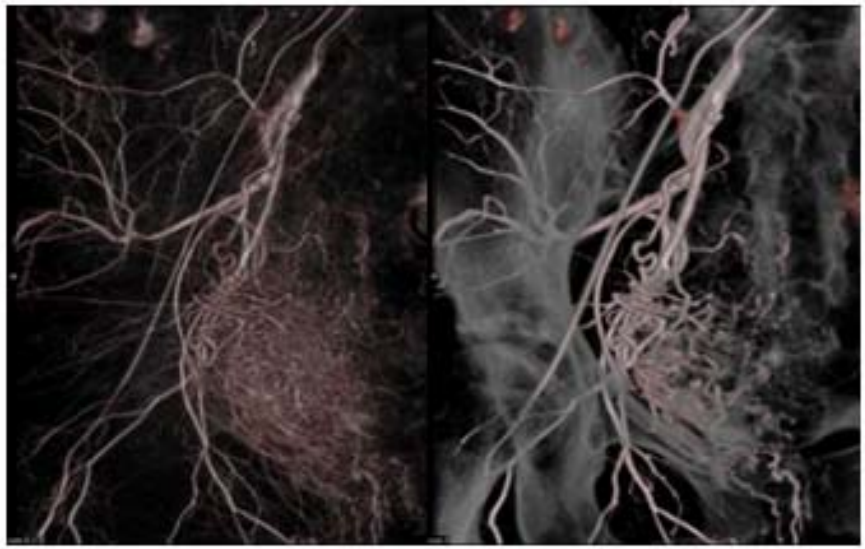

"DynaCT can also provide three dimensional information. Spatial relationship between vessel and other vessel or bone is clearly shown on VR image processed by DSA and DA data."

Welche klinischen Anwendungen können von DynaCT profitieren ?

- **Neuro**
  - Darstellung von Rupturen und “langsamen” Blutungen
  - Unterstützung bei Drainagen
  - Darstellung der zerebralen Ventrikel
- **Biopsien / Drainagen / Punktionen**
  - Nephrostomie
  - Gastrostomie
  - Gallengangsdrainage
  - TIPS
- **Tumorbehandlung**
  - Darstellung des Tumors und der versorgenden Gefäße
  - Behandlung des Tumors
    - Embolisation
    - RF Ablation
- **Management von Komplikationen**

Ausblick – was kommt nun ?



Ausblick – Cardiac DynaCT

- Tierexperiment im AXIOM Lab @ Stanford
- Parallele Bildakquisition & EKG Aufnahme
- EKG-gesteuerte Rekonstruktion

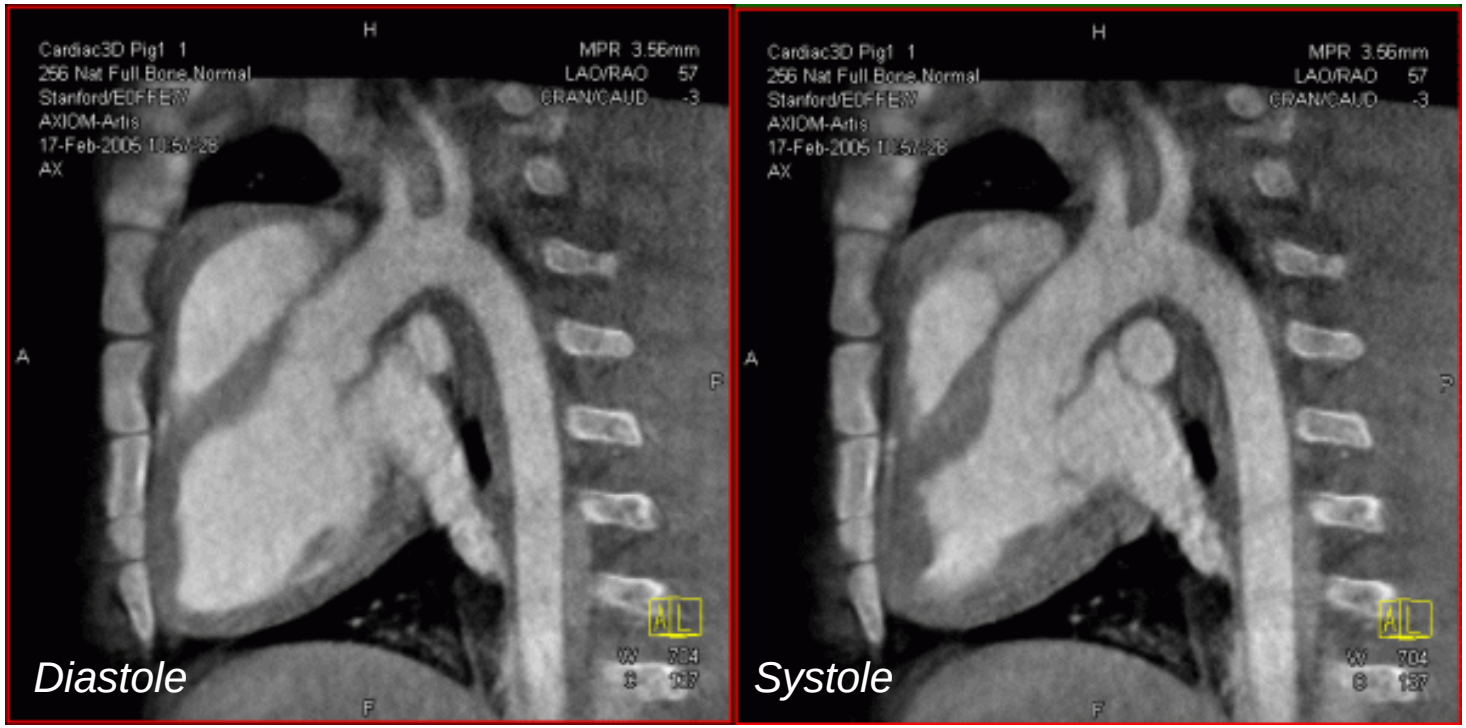

Siemens **Medical**
Solutions that help