Die Digitale Volumentomographie in der Zahnmedizin und MKG-Chirurgie

Priv.-Doz. Dr. Dr. Alexander Schramm

Leitender Oberarzt
Klinik für Mund-, Kiefer-, Gesichtschirurgie
Medizinische Hochschule Hannover
Dir.: Prof. Dr. Dr. N.-C. Gellrich

Der Digitale Volumentomograph

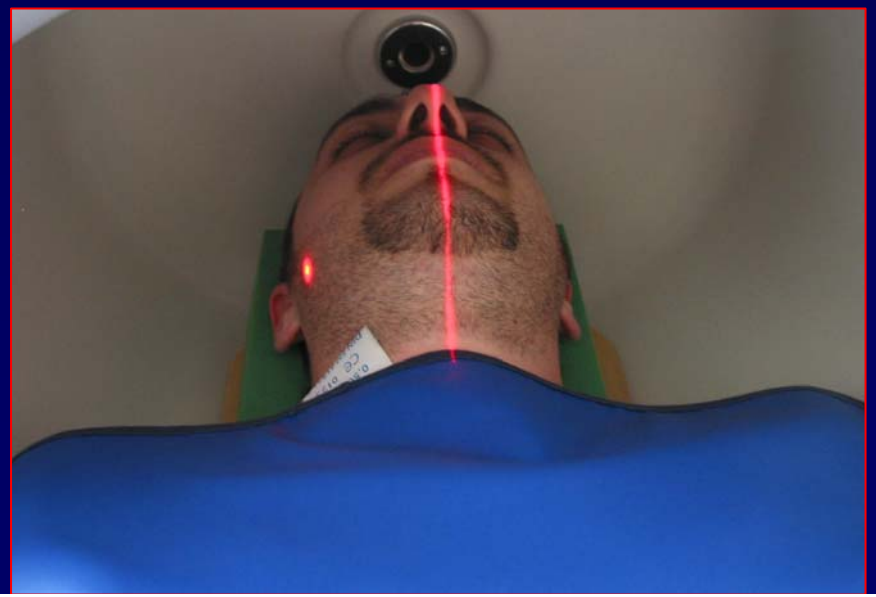

Laserstrahlen zur Kopfjustierung

Digitales Volumen-Tomogramm (DVT)

- kegelförmiger Röntgenstrahl
- 360° Rotation
- 1 Rohdatenerfassung pro Winkelgrad

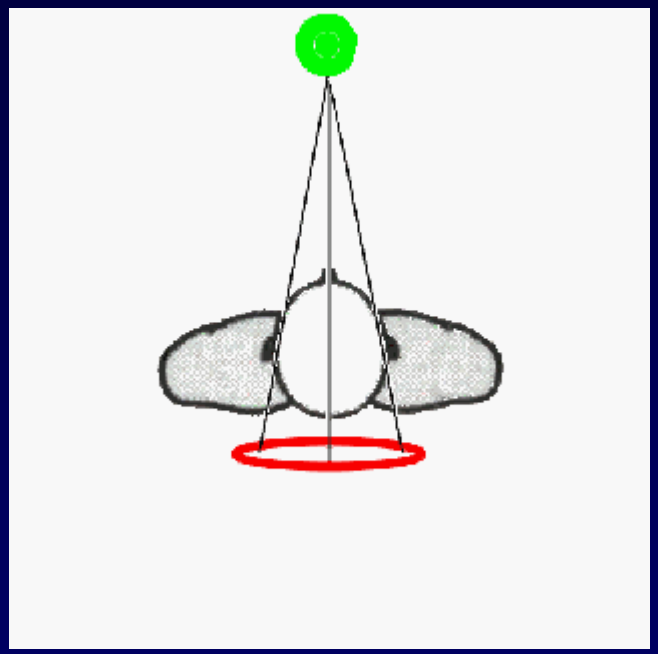

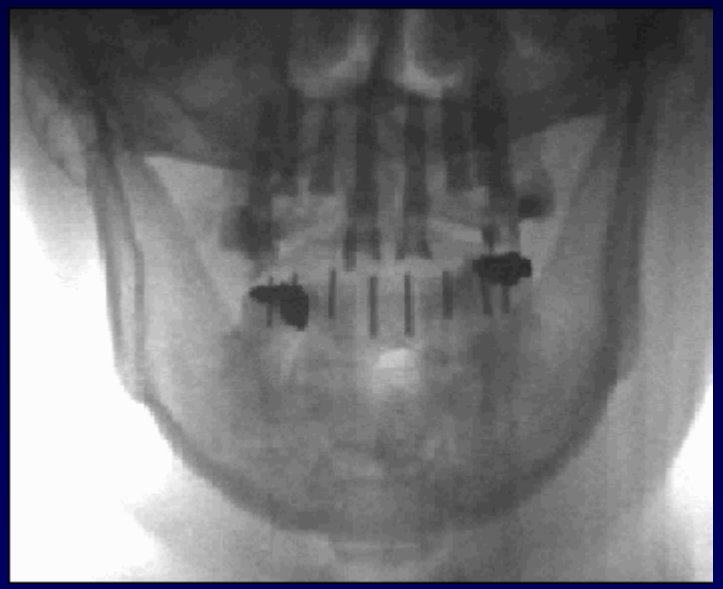

- Aufnahmezeit maximal 76 s
- Strahlenexpositionszeit 36 s
- Strahlenbelastung ca. 4-fach geringer als bei der CT-Untersuchung

Bildgebung
Axiale Schichtung

orthogonal zur Rotationsachse

Schichtebene variabel einstellbar (z.B. parallel zur Okklusionsebene)

Schichtdicke: 0.3mm / 1mm / 2mm

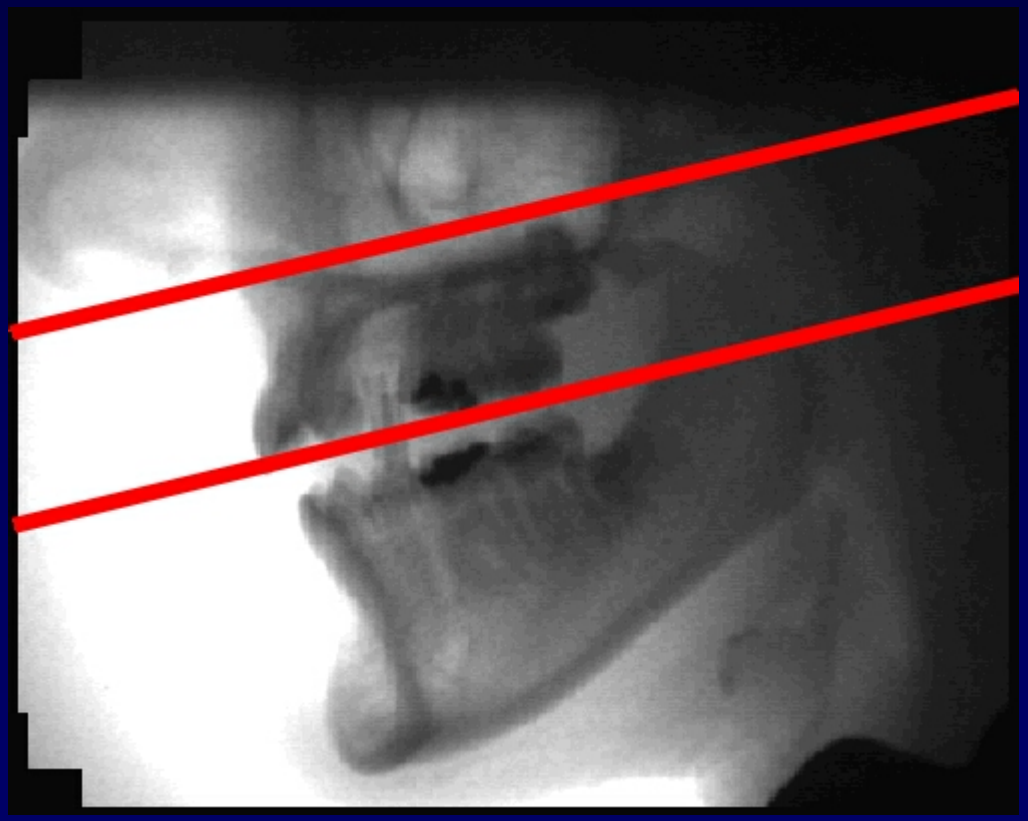

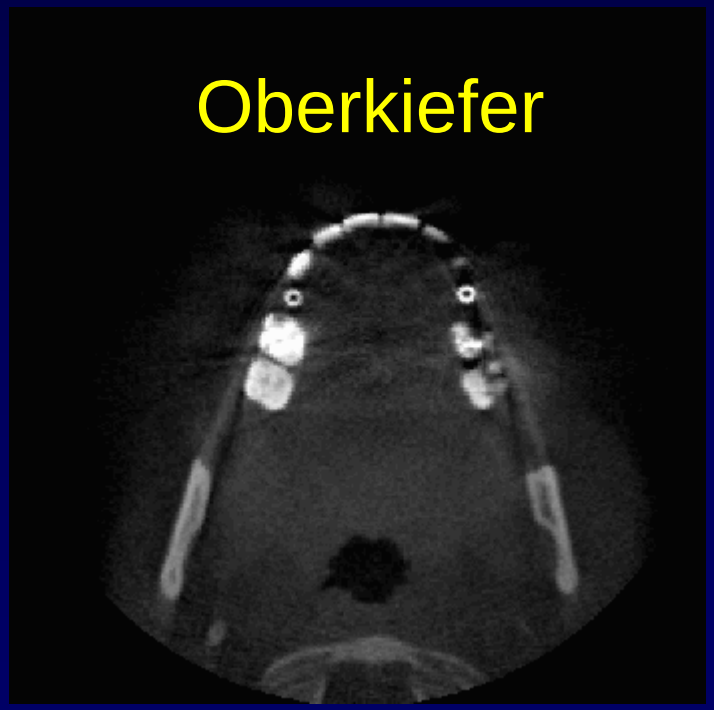

Bildgebung
Axiale Schichtung

orthogonal zur Rotationsachse

Schichtebene variabel einstellbar (z.B. parallel zur Okklusionsebene)

Schichtdicke: 0.3mm / 1mm / 2mm

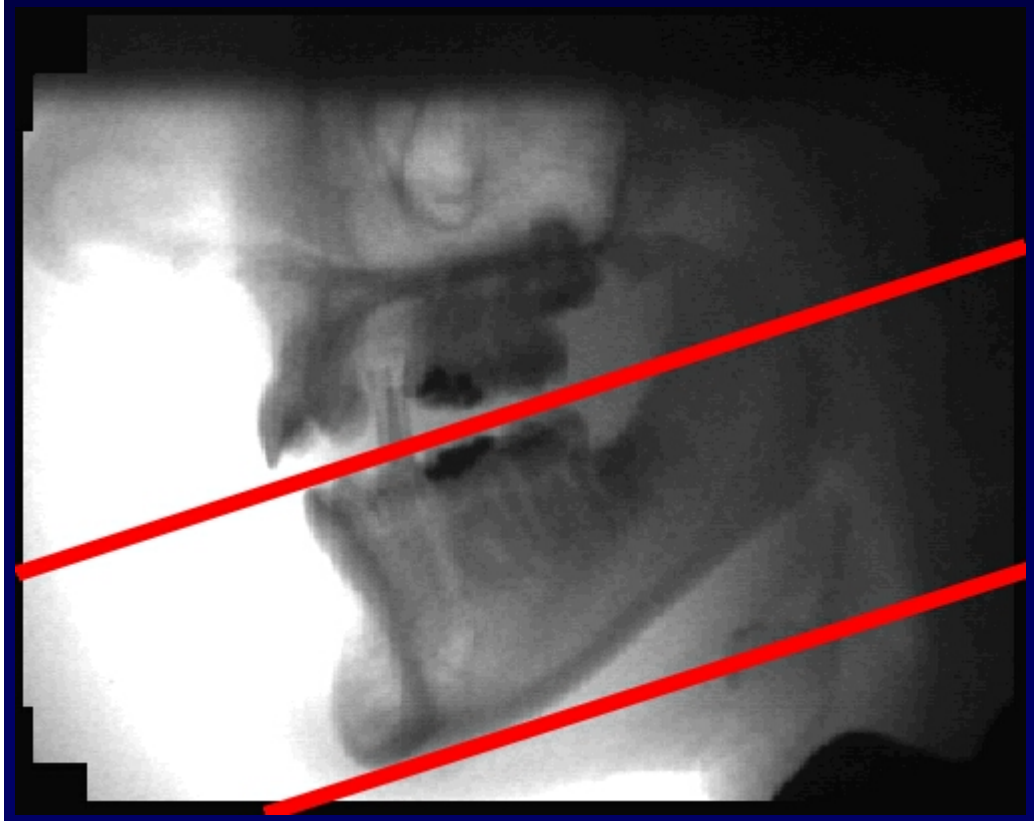

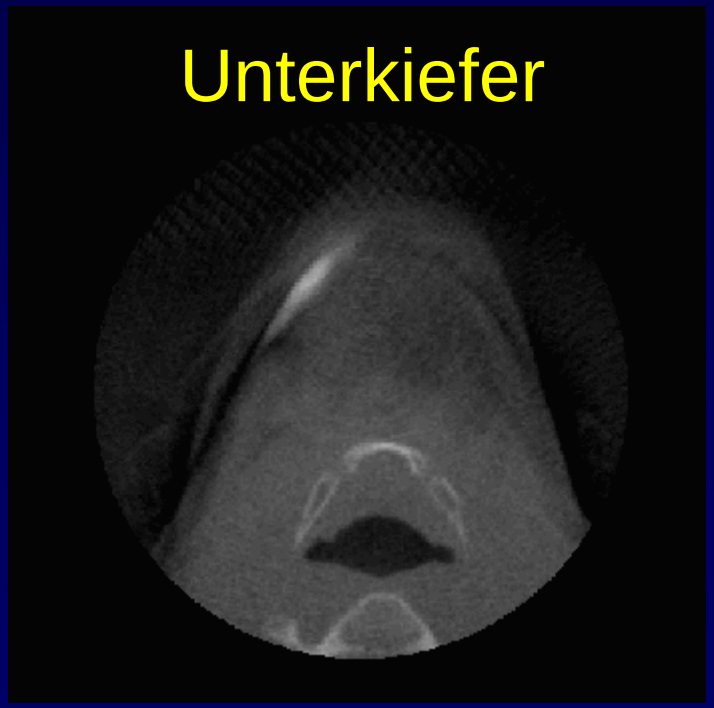

Bildverarbeitung

Paraaxiale Schichtung

2-D-Rekonstruktion senkrecht zur Horizontalebene

Einzelschichten oder Sequenzen

Schichtdicke: 0.5mm / 1mm / 2mm / 3mm / 5mm

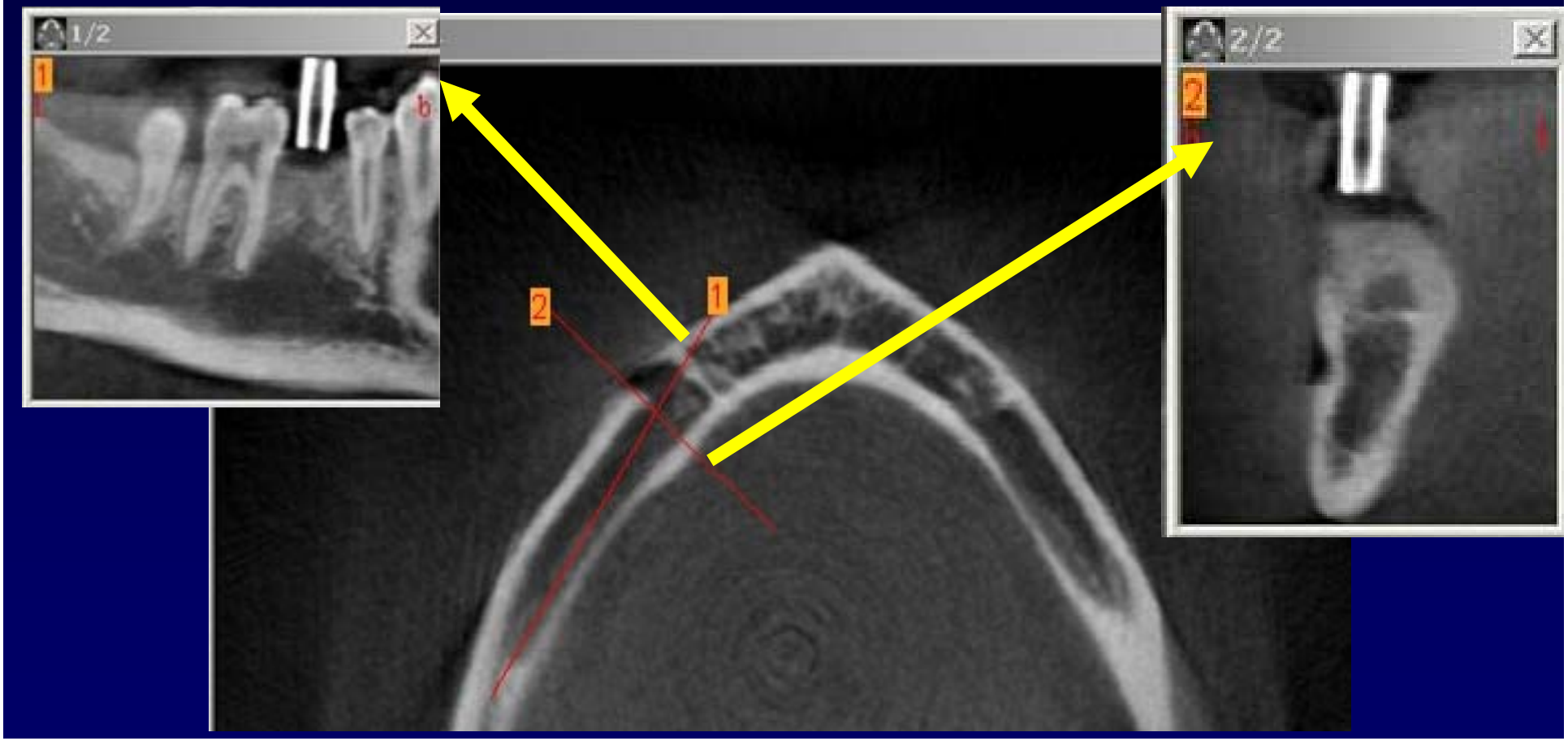

Bildverarbeitung

Panoramaschichtung

2-D-Rekonstruktion senkrecht zur Horizontalebene

Einzelbildprojektion bezogen auf die Unterkieferparabel

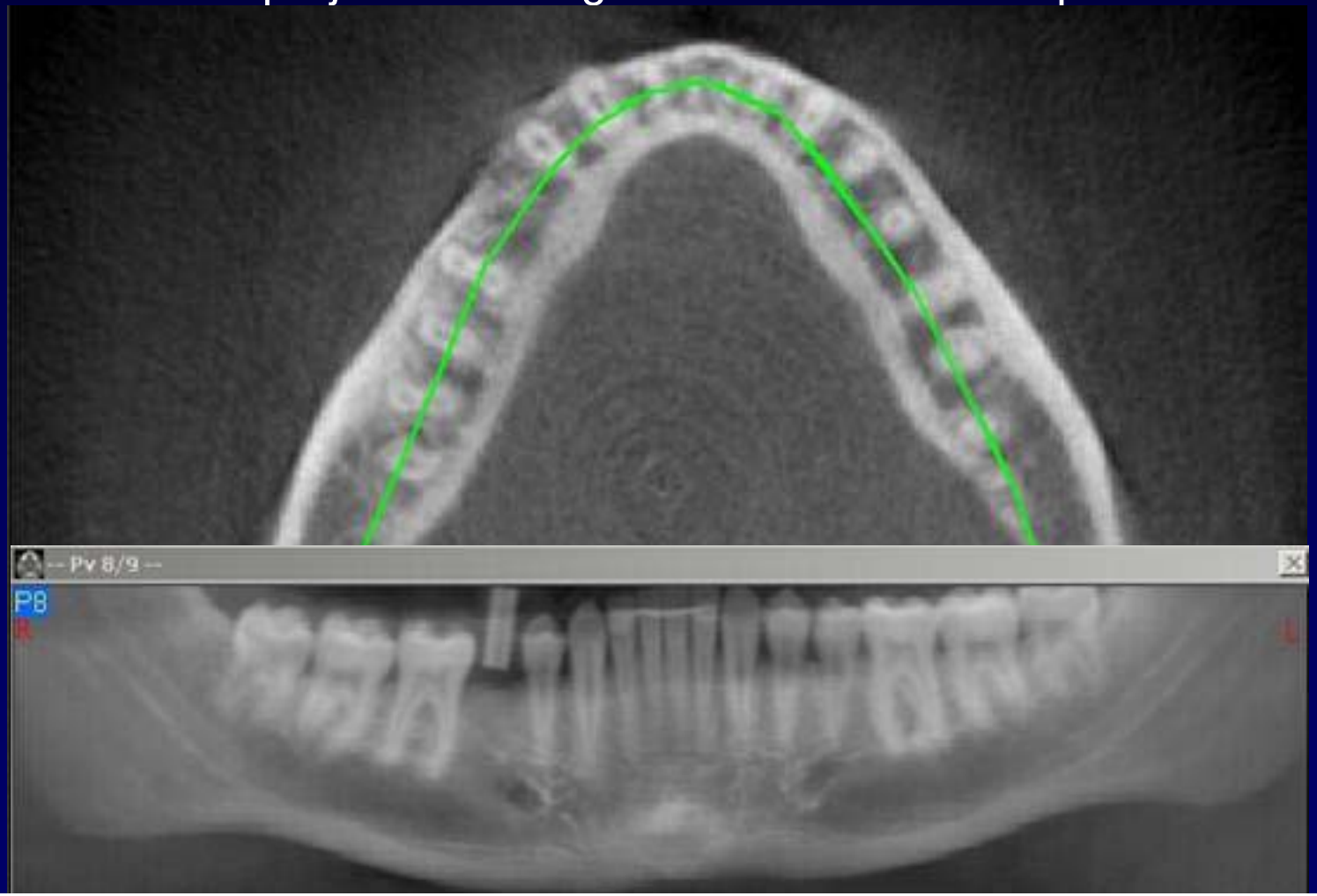

Bildverarbeitung

3D-Rekonstruktion

nach definiertem Volumen

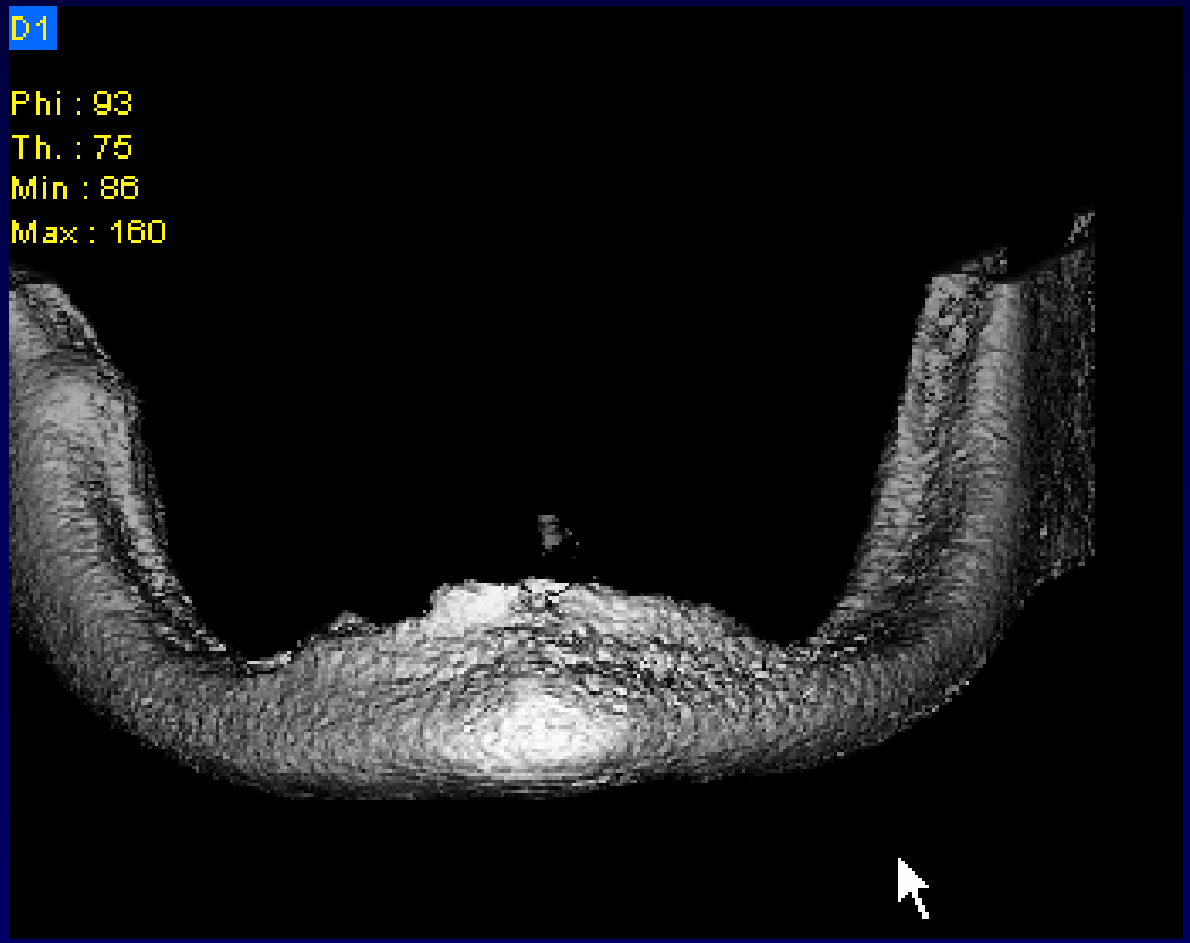

Verlagerter Zahn 38

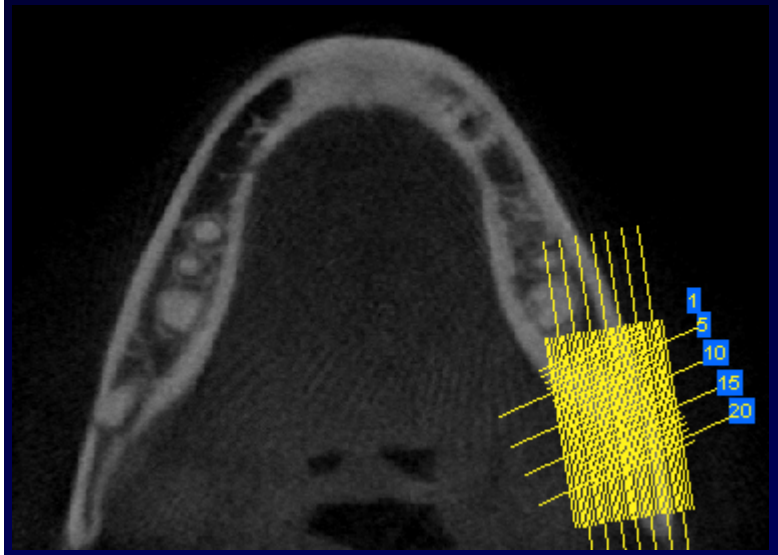

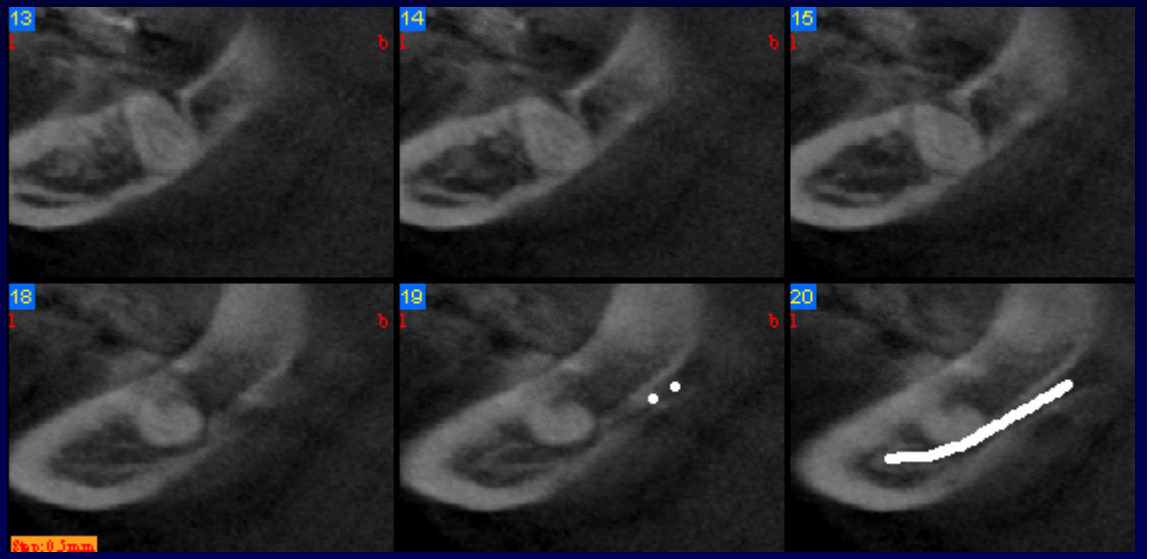

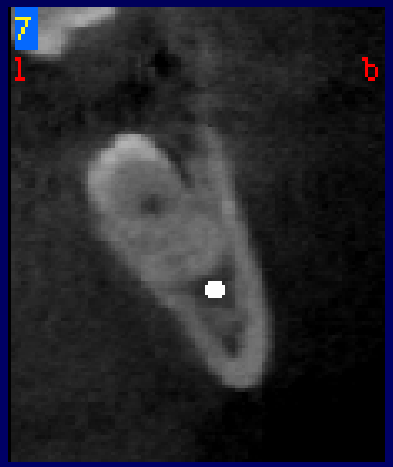

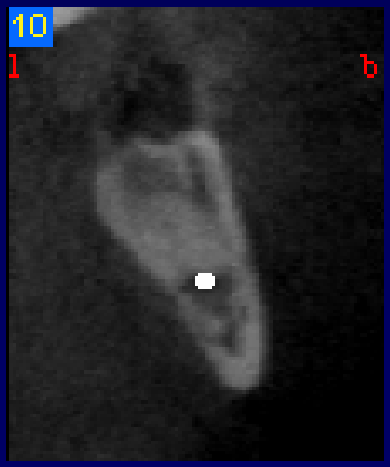

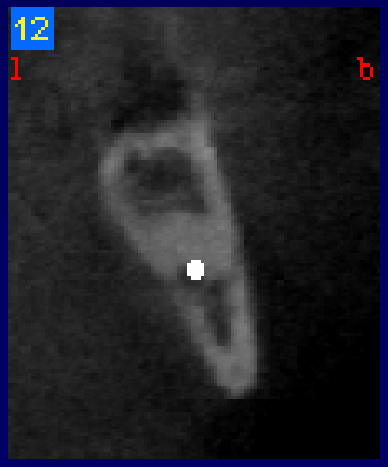

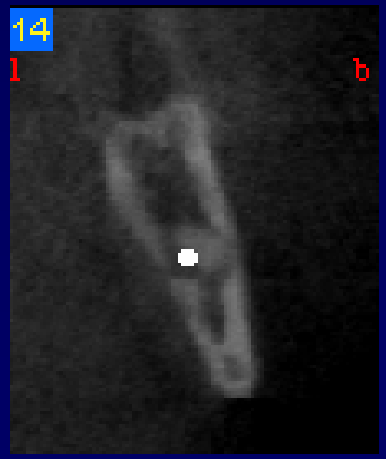

Implantatplanung

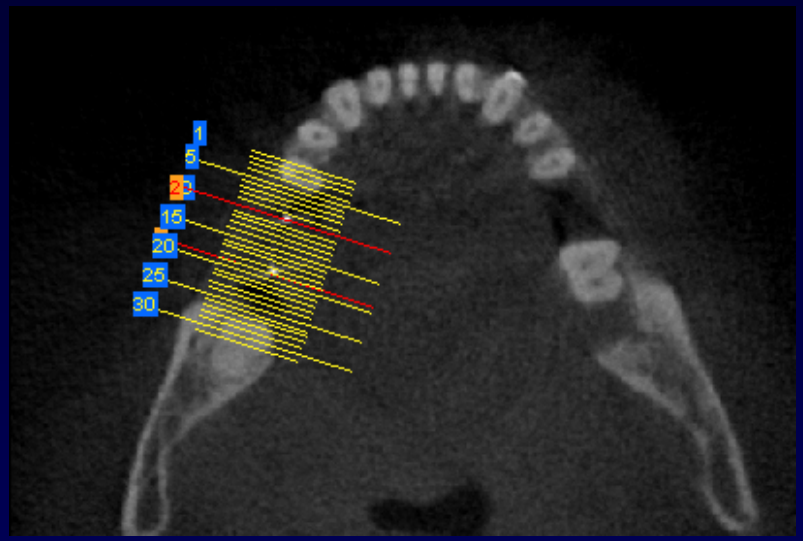

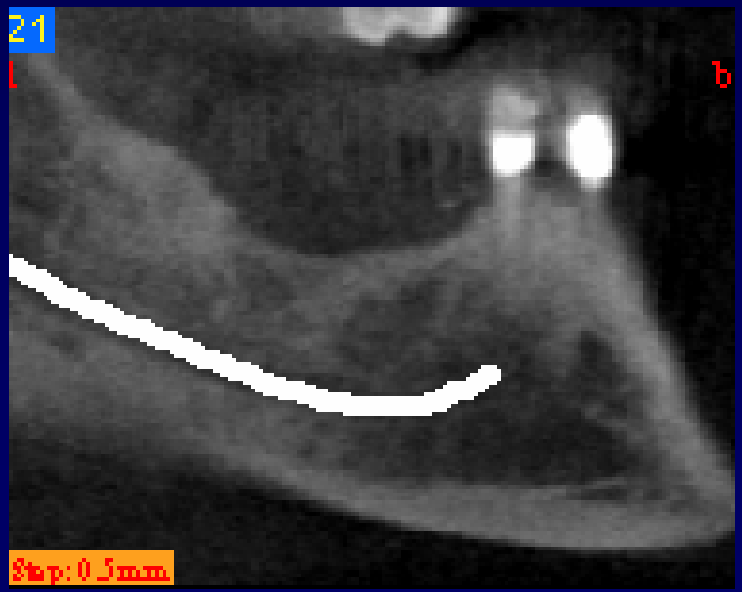

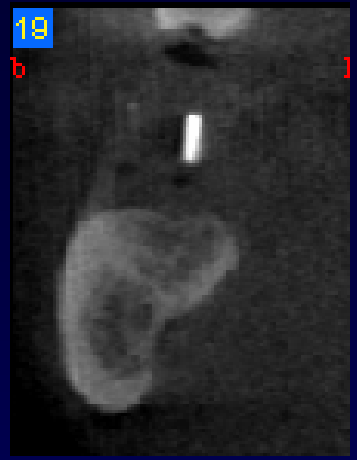

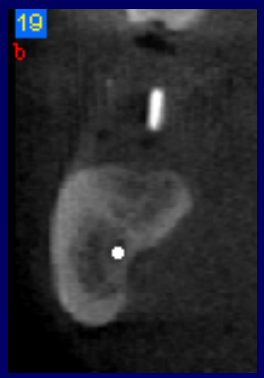

Präimplantologische Planung

Nach Sinuslift

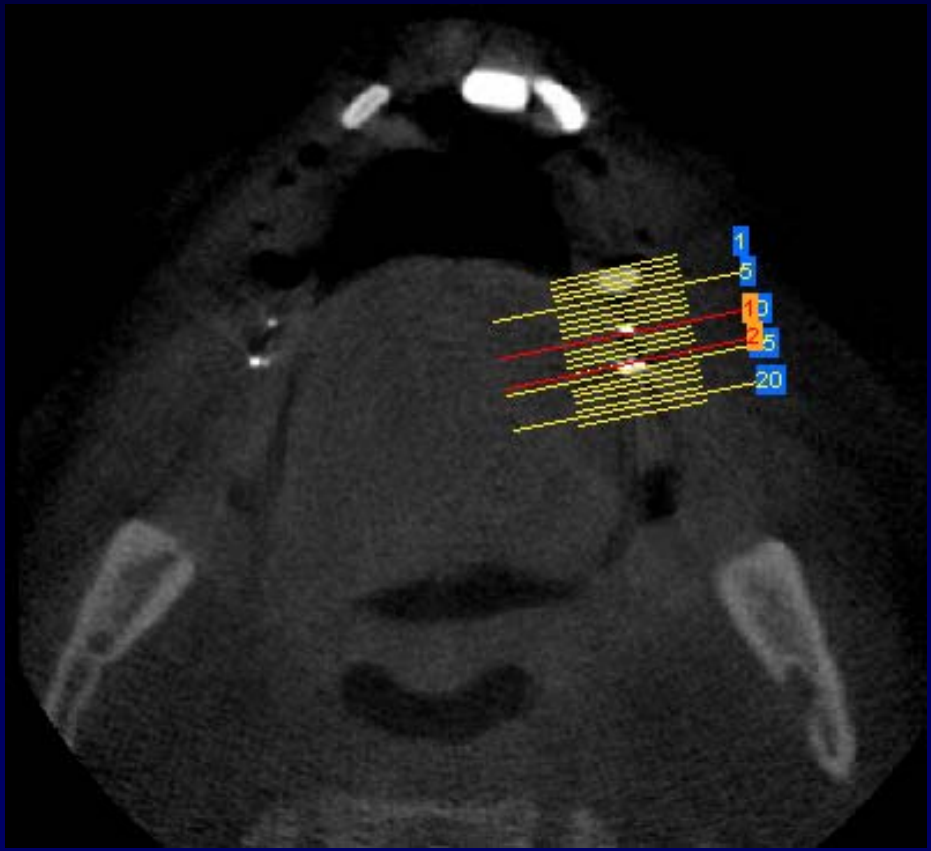

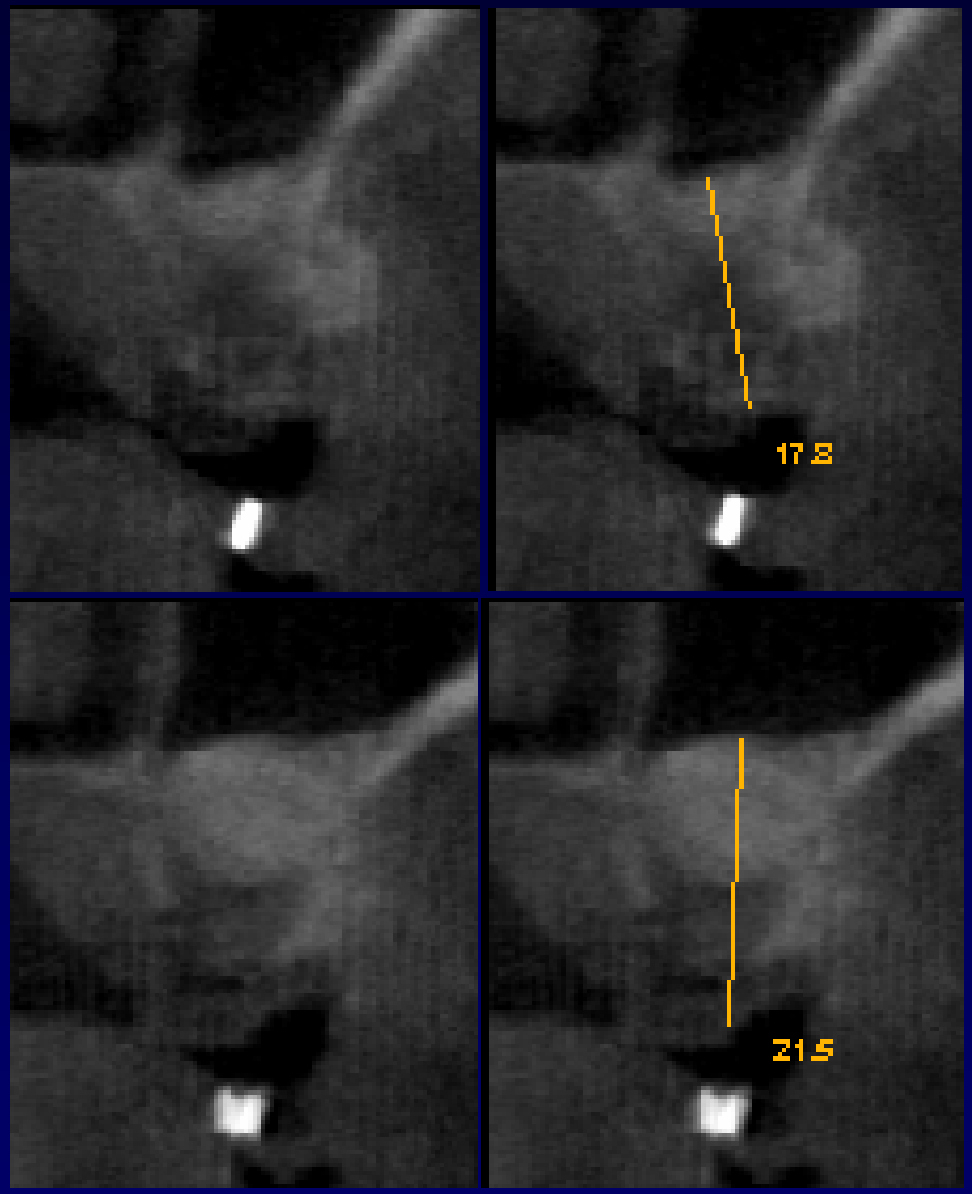

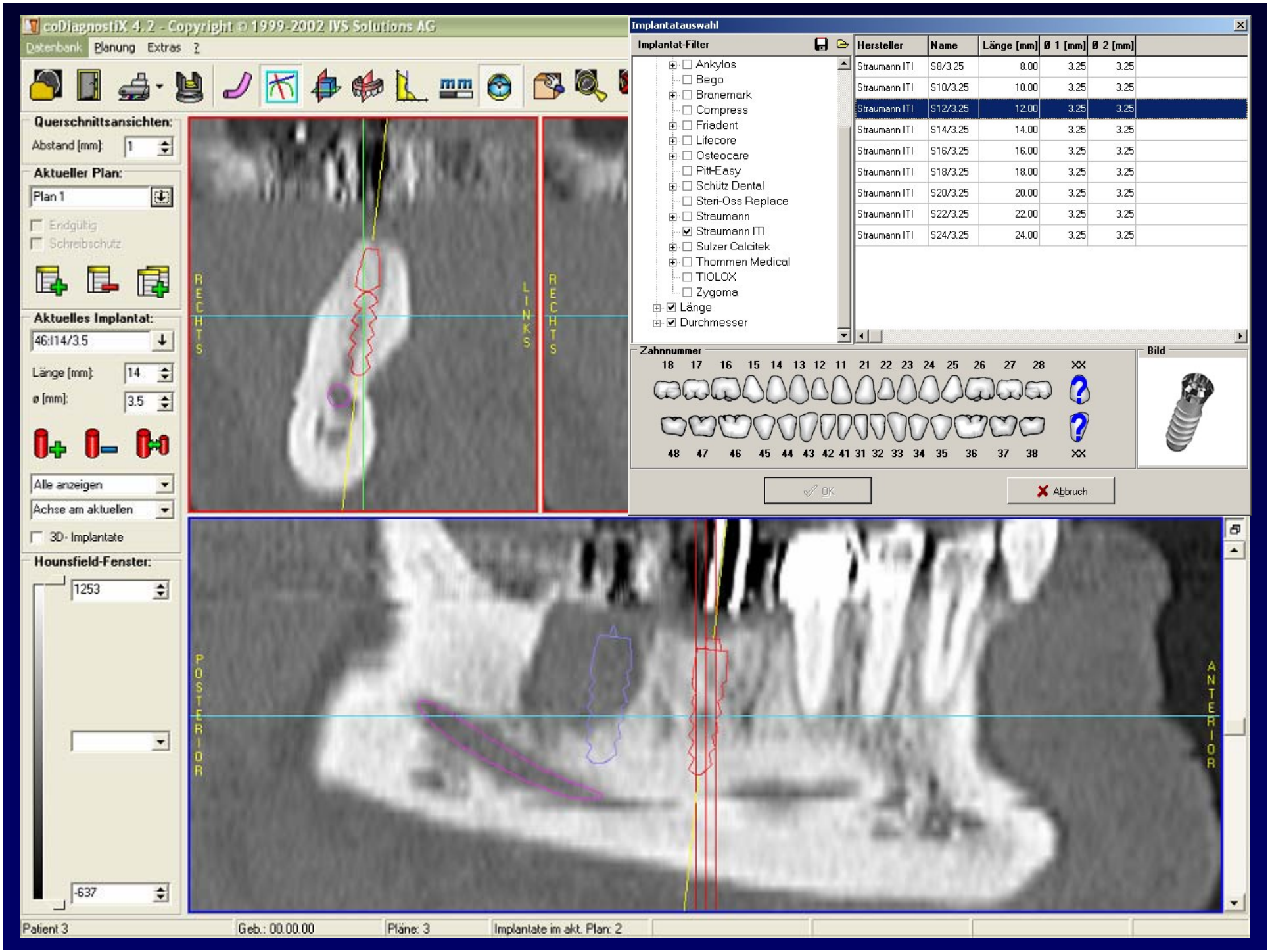
coDiagnostiX 4.2 - Copyright © 1999-2002 IVS Solutions AG
Datenbank Planung Extras ?
Querschnittsansichten:
Abstand [mm]: 1
Aktueller Plan:
Plan 1
Endgültig
Schreibschutz
Aktuelles Implantat:
46:I14/3.5
Länge [mm]: 14
ø [mm]: 3.5
Alle anzeigen
Achse am aktuellen
3D- Implantate
Hounsfield-Fenster:
1253
-637
RECHTS
LINKS
RECHTS
POSTERIOR
ANTERIOR
Implantatauswahl
Implantat-Filter
Ankylos
Bego
Branemark
Compress
Friadent
Lifecore
Osteocare
Pitt-Easy
Schütz Dental
Steri-Oss Replace
Straumann
Straumann ITI
Sulzer Calcitek
Thommen Medical
TIOLOX
Zygoma
Länge
Durchmesser
Hersteller | Name | Länge [mm] | Ø 1 [mm] | Ø 2 [mm]
Straumann ITI | S8/3.25 | 8.00 | 3.25 | 3.25
Straumann ITI | S10/3.25 | 10.00 | 3.25 | 3.25
Straumann ITI | S12/3.25 | 12.00 | 3.25 | 3.25
Straumann ITI | S14/3.25 | 14.00 | 3.25 | 3.25
Straumann ITI | S16/3.25 | 16.00 | 3.25 | 3.25
Straumann ITI | S18/3.25 | 18.00 | 3.25 | 3.25
Straumann ITI | S20/3.25 | 20.00 | 3.25 | 3.25
Straumann ITI | S22/3.25 | 22.00 | 3.25 | 3.25
Straumann ITI | S24/3.25 | 24.00 | 3.25 | 3.25
Zahnnummer
18 17 16 15 14 13 12 11 21 22 23 24 25 26 27 28 XX
48 47 46 45 44 43 42 41 31 32 33 34 35 36 37 38 XX
Bild
OK
Abbruch
Patient 3
Geb.: 00.00.00
Pläne: 3
Implantate im akt. Plan: 2

Fallbeispiel Dentalnavigation

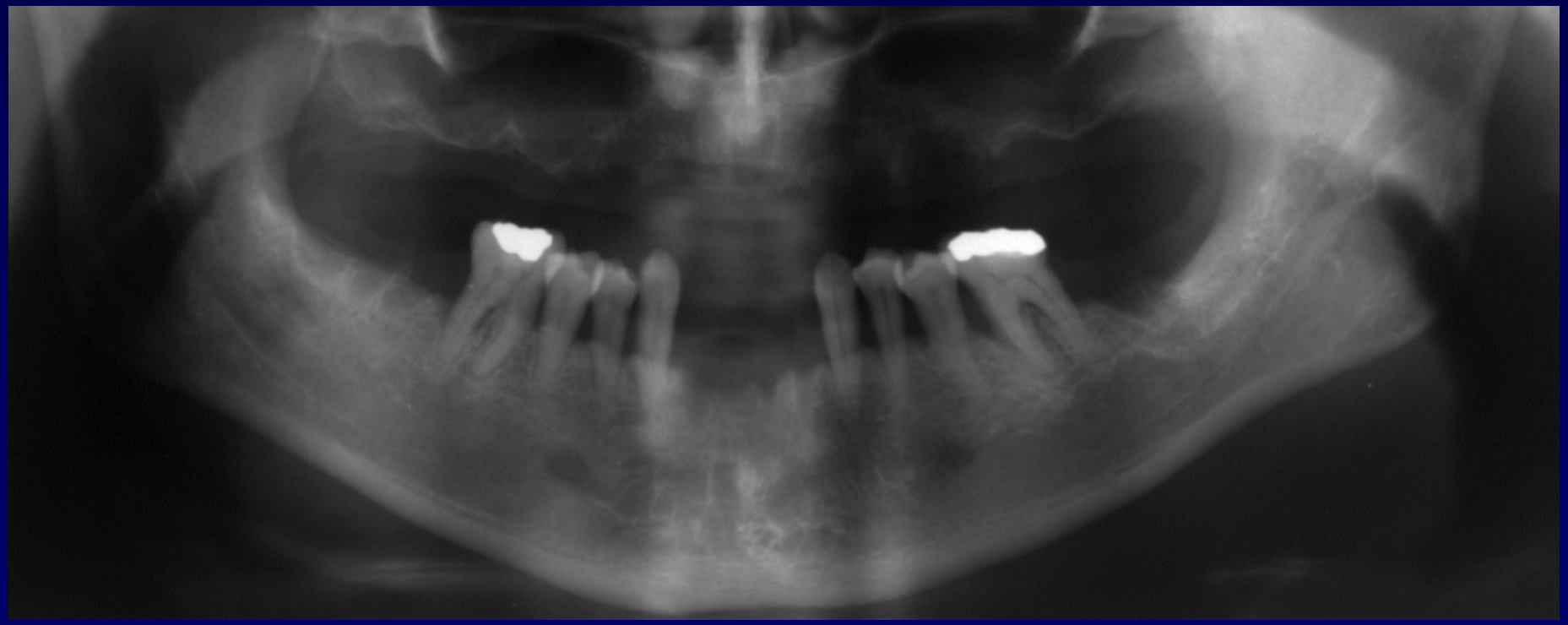

Präperatives Set up

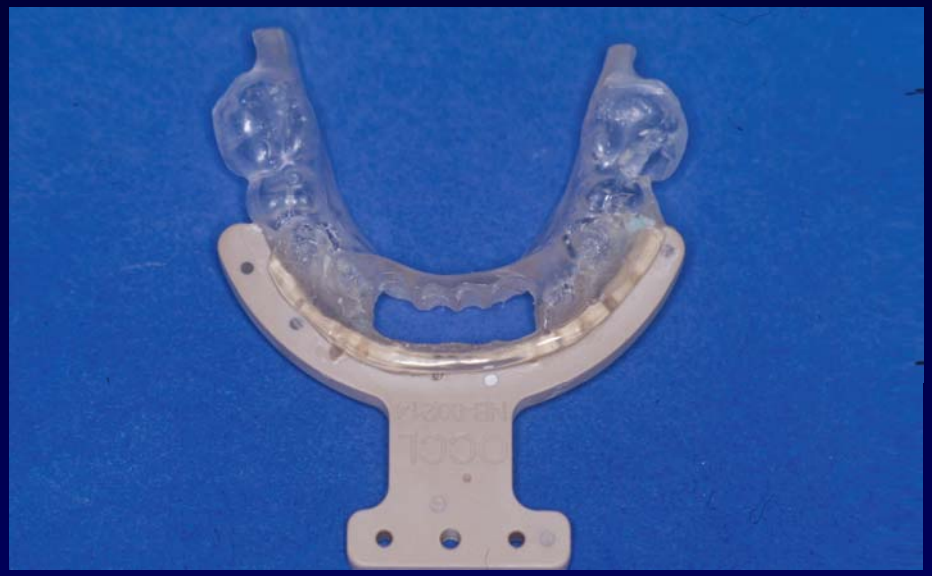

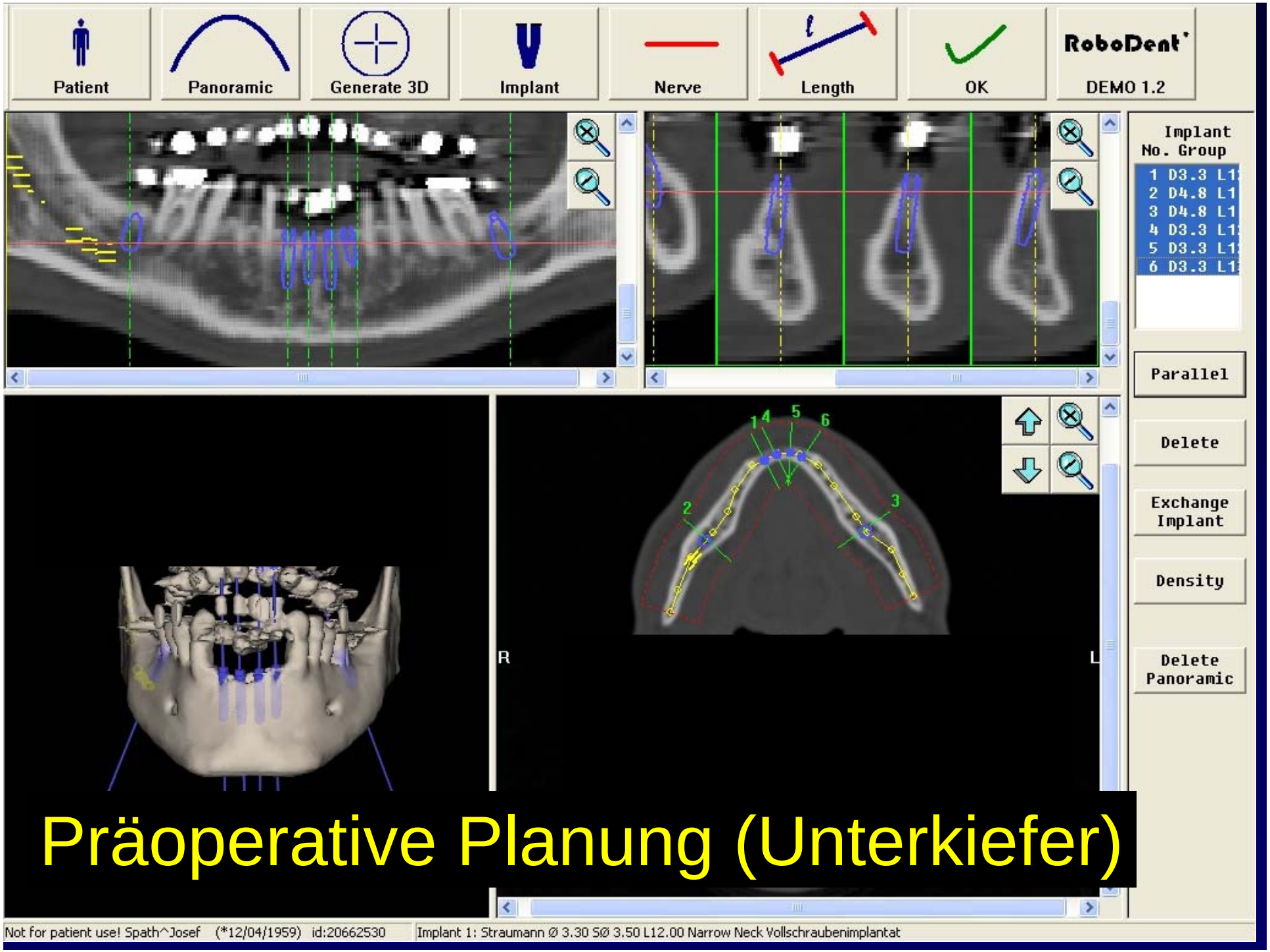

Präoperative Planung (Unterkiefer)

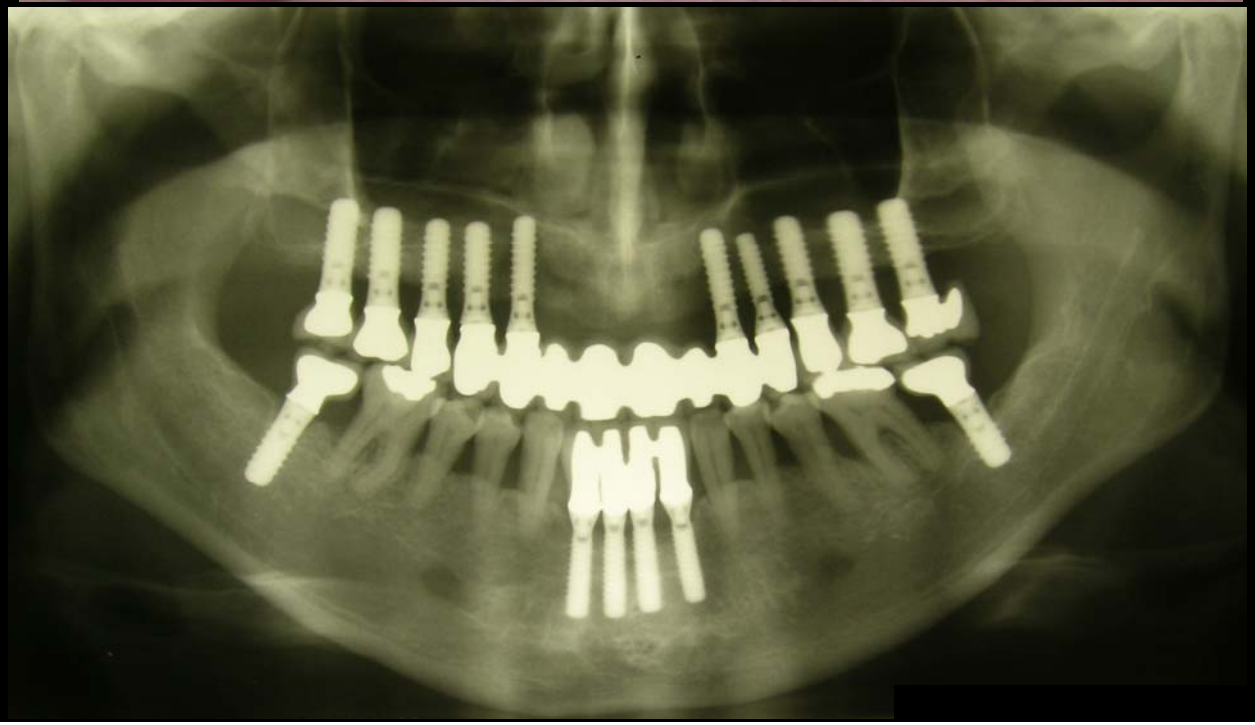

Gelenkfortsatzfrakturen

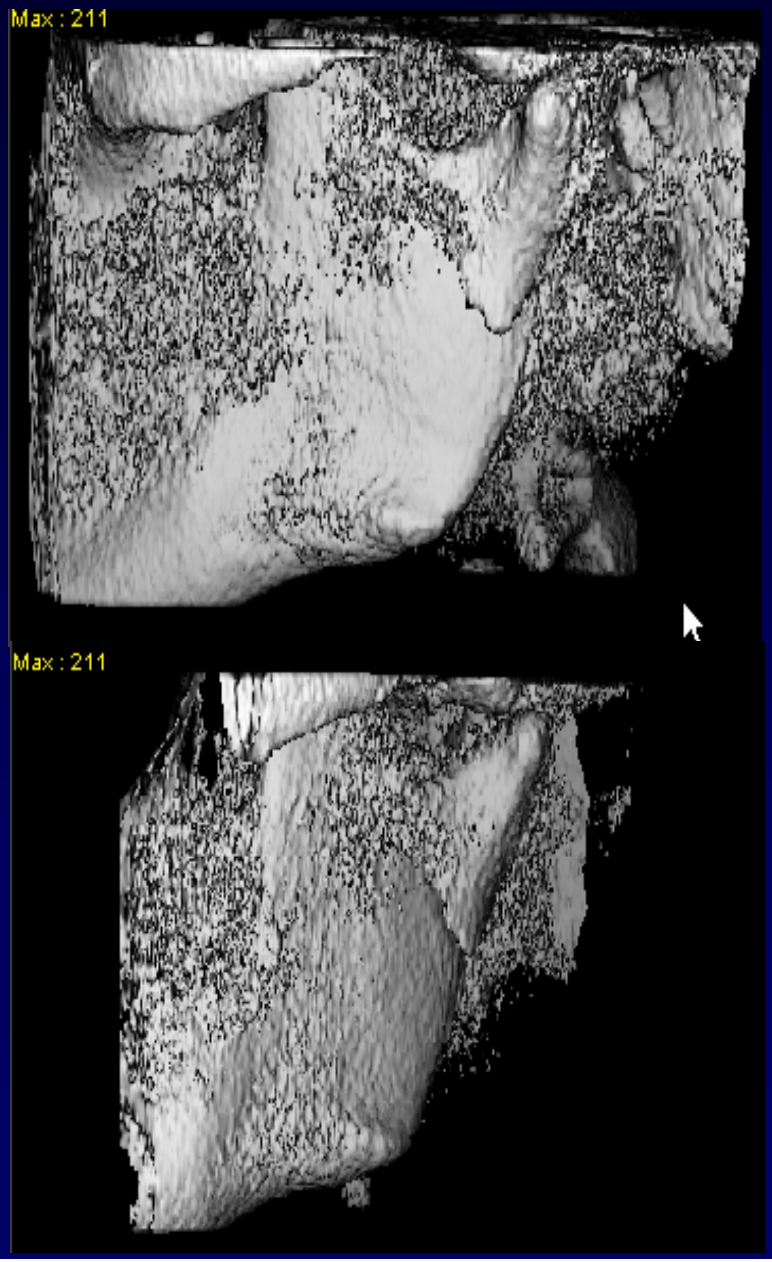

Intraoraler Zugang

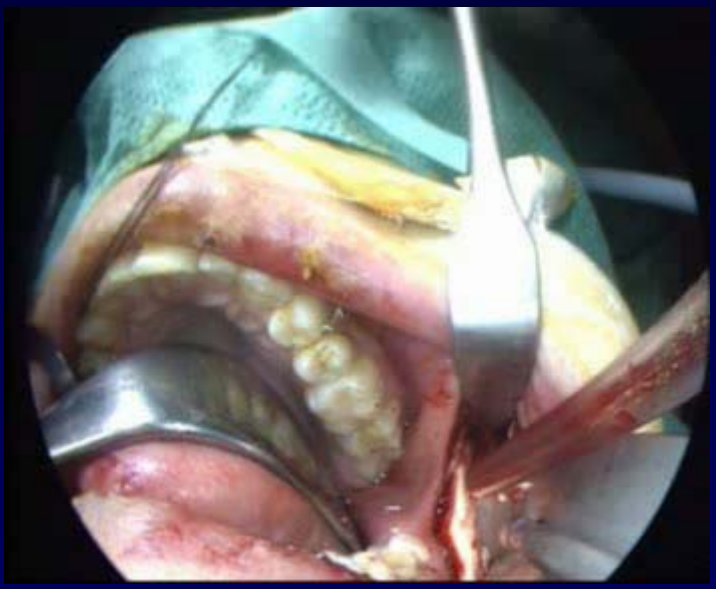

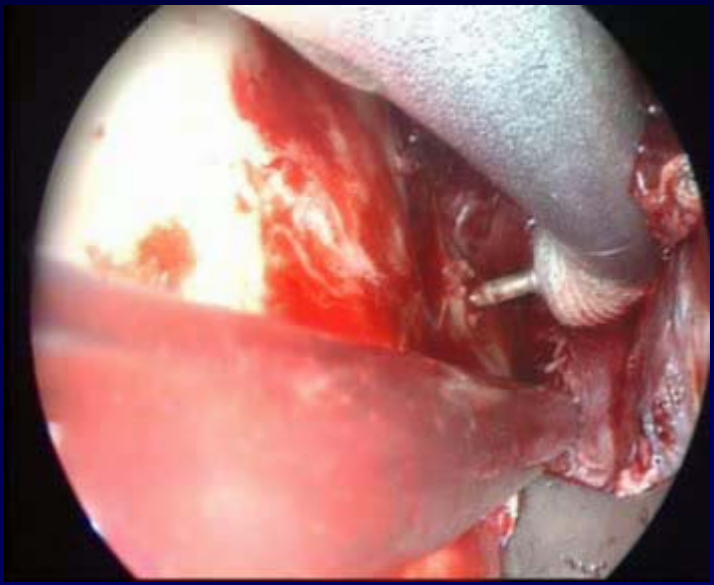

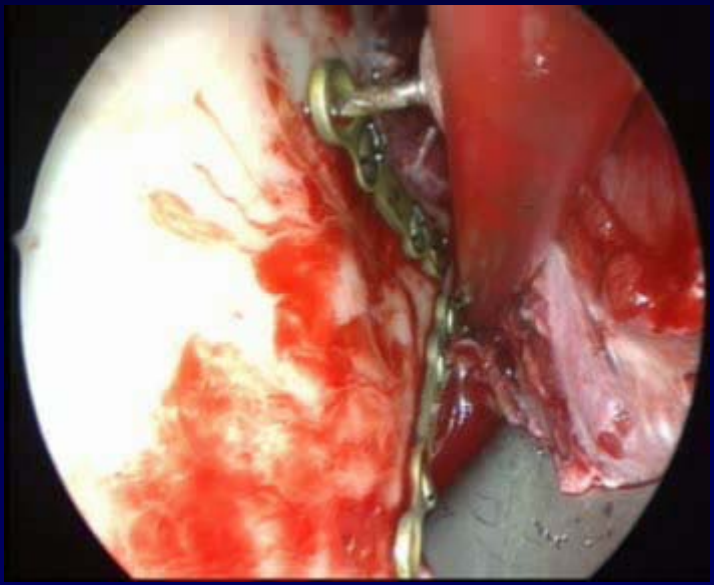

Erstellung einer virtuellen Schablone

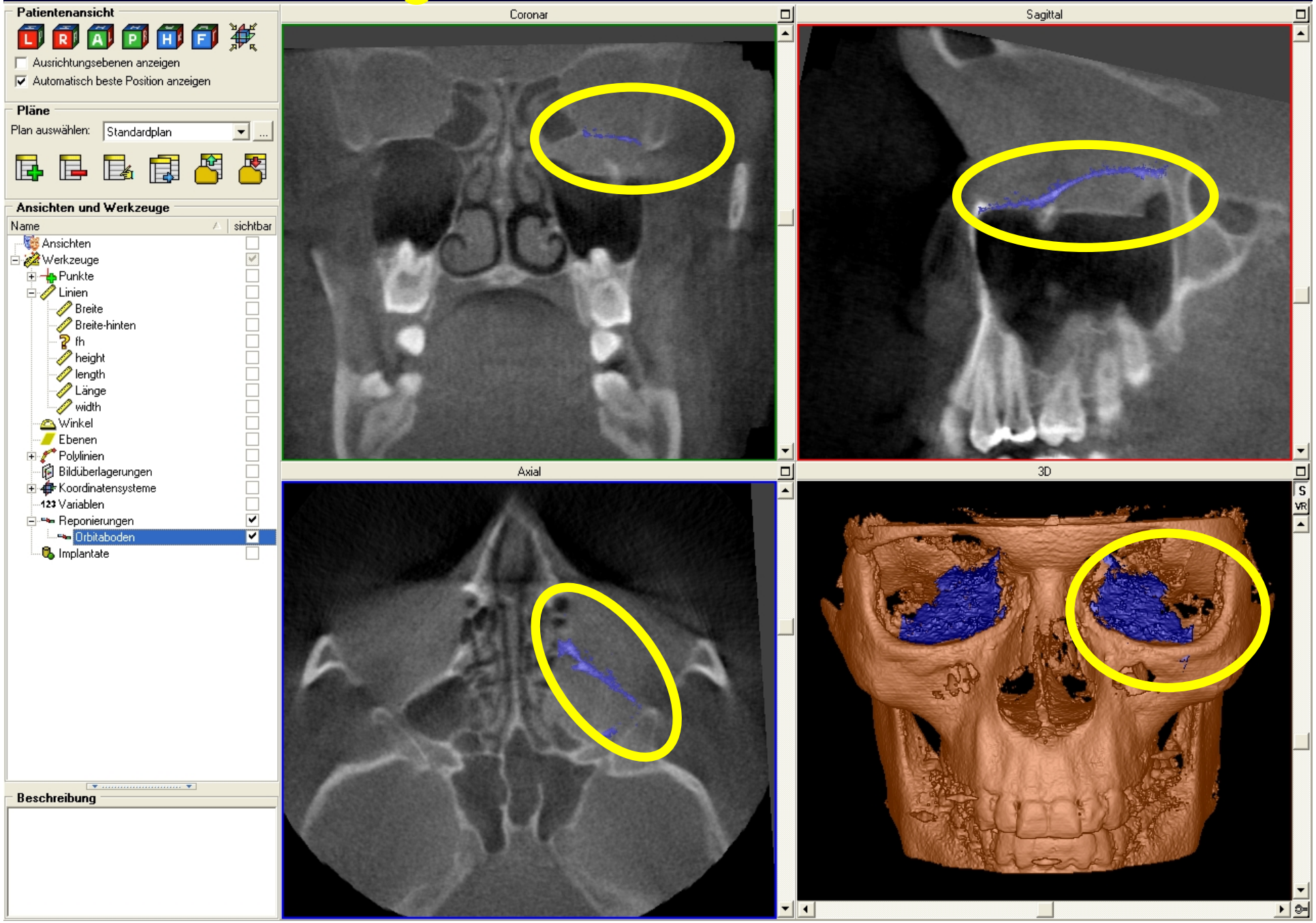

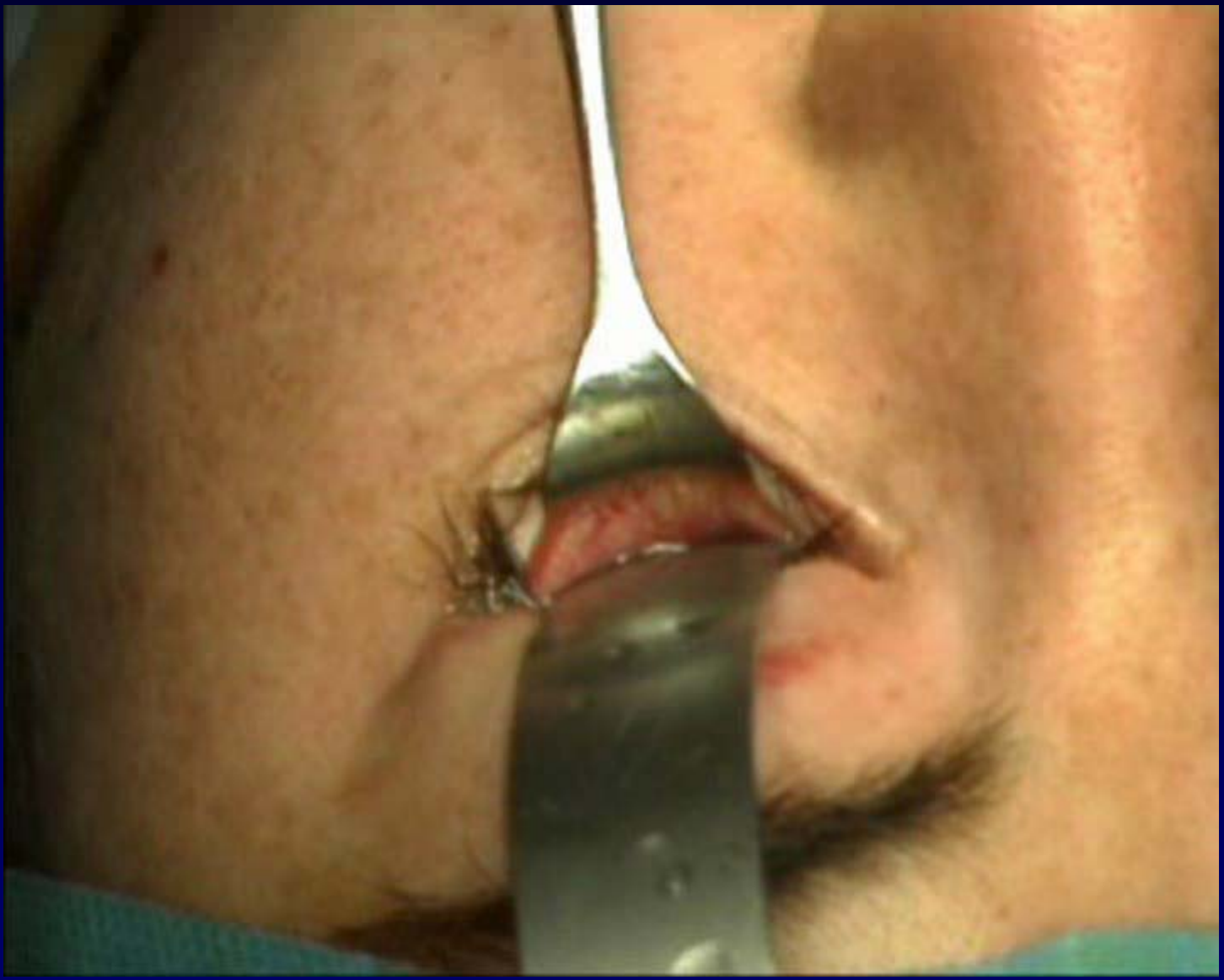

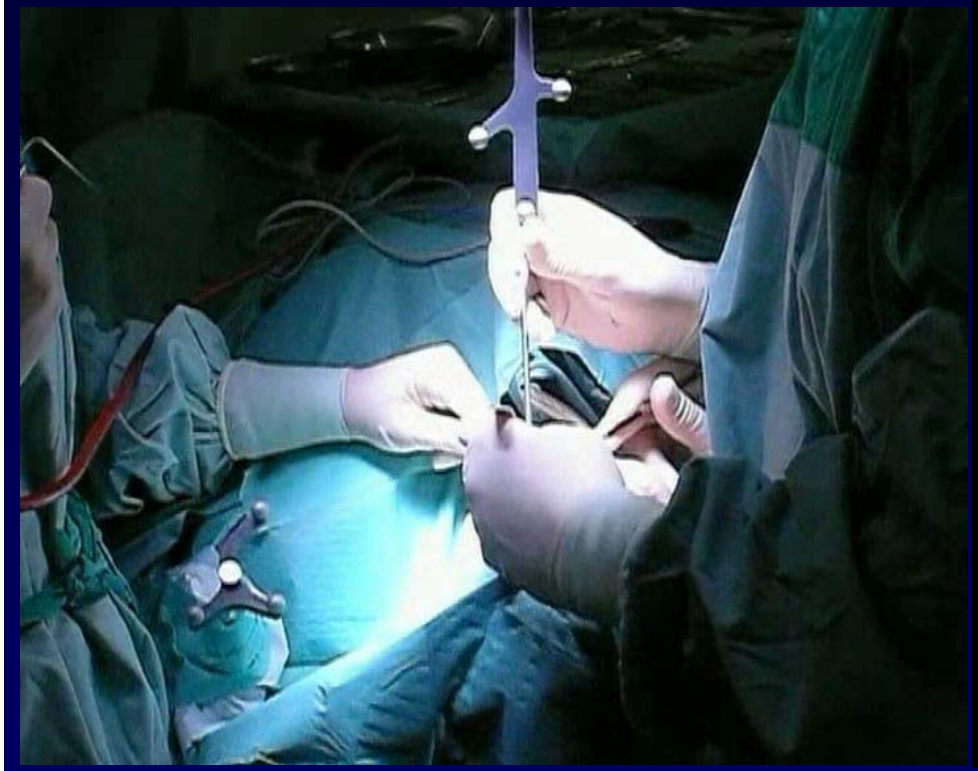

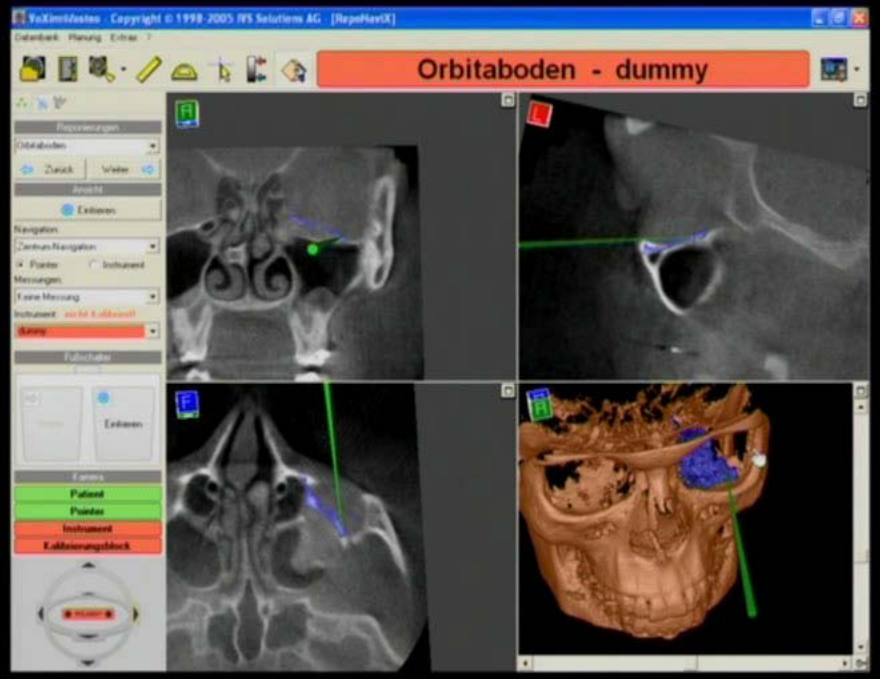
Orbitaboden - dummy

Postoperative Kontrolle (DVT)

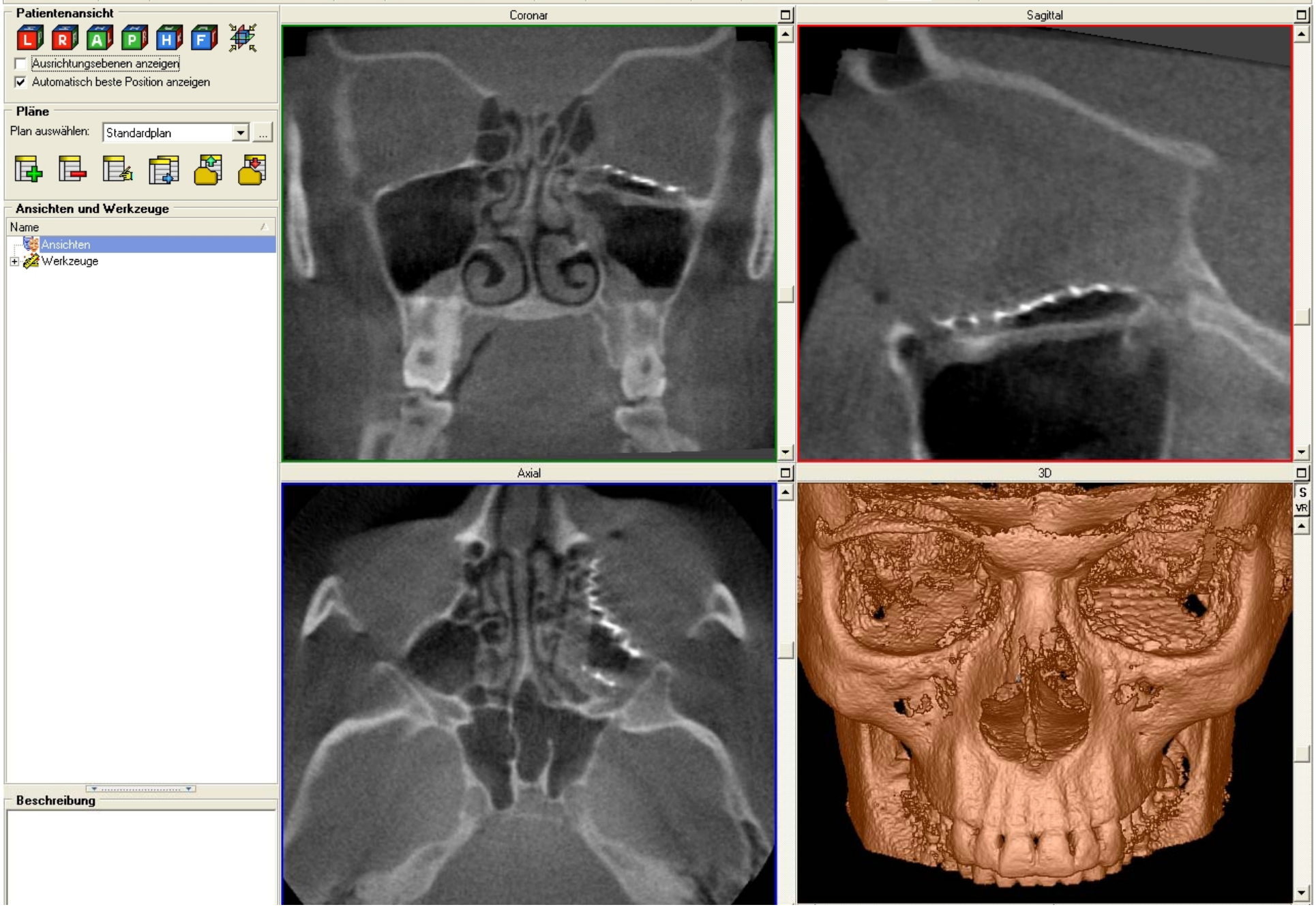

Postoperative Kontrolle
Image Fusion

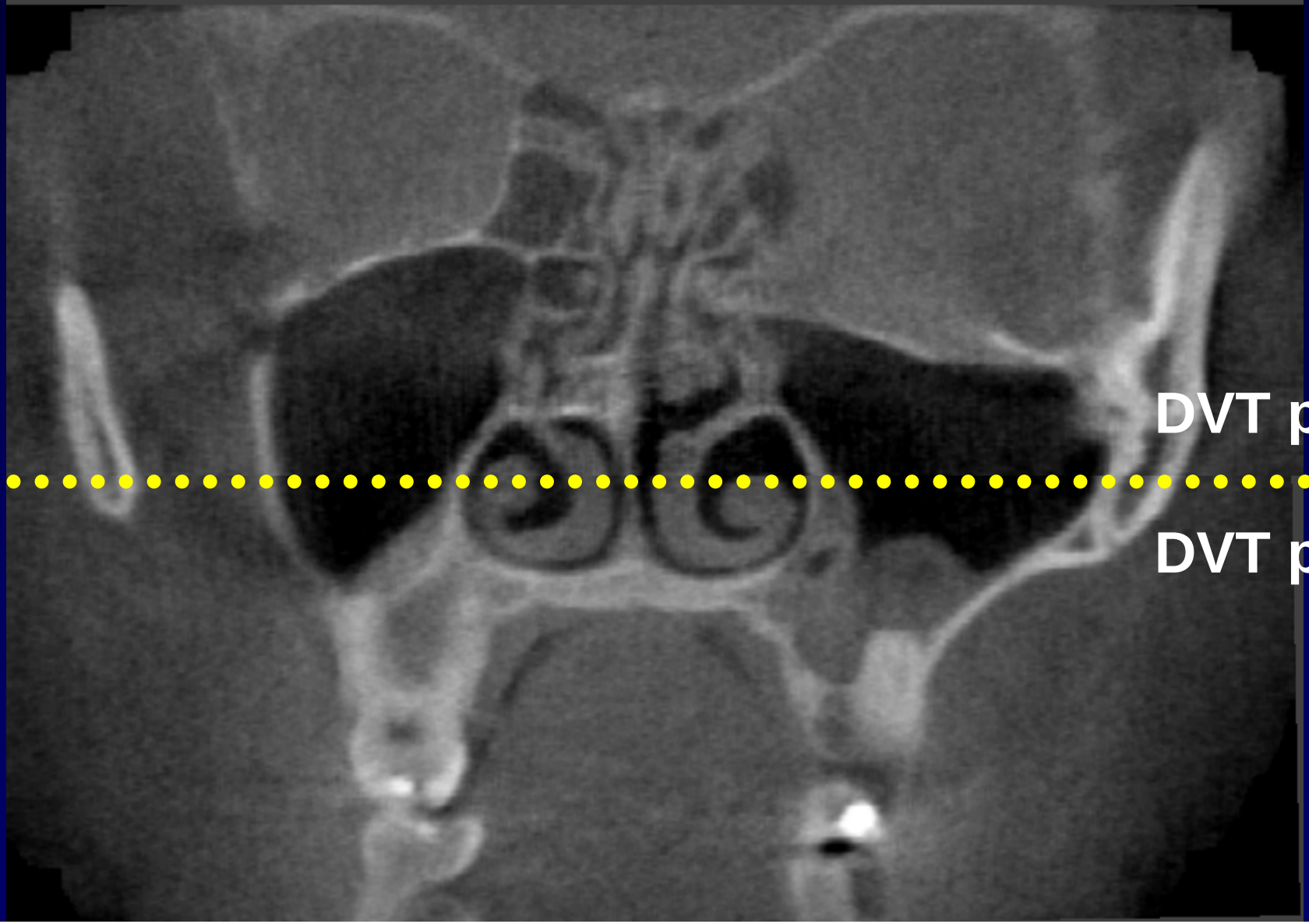

Postoperative Kontrolle
Image Fusion

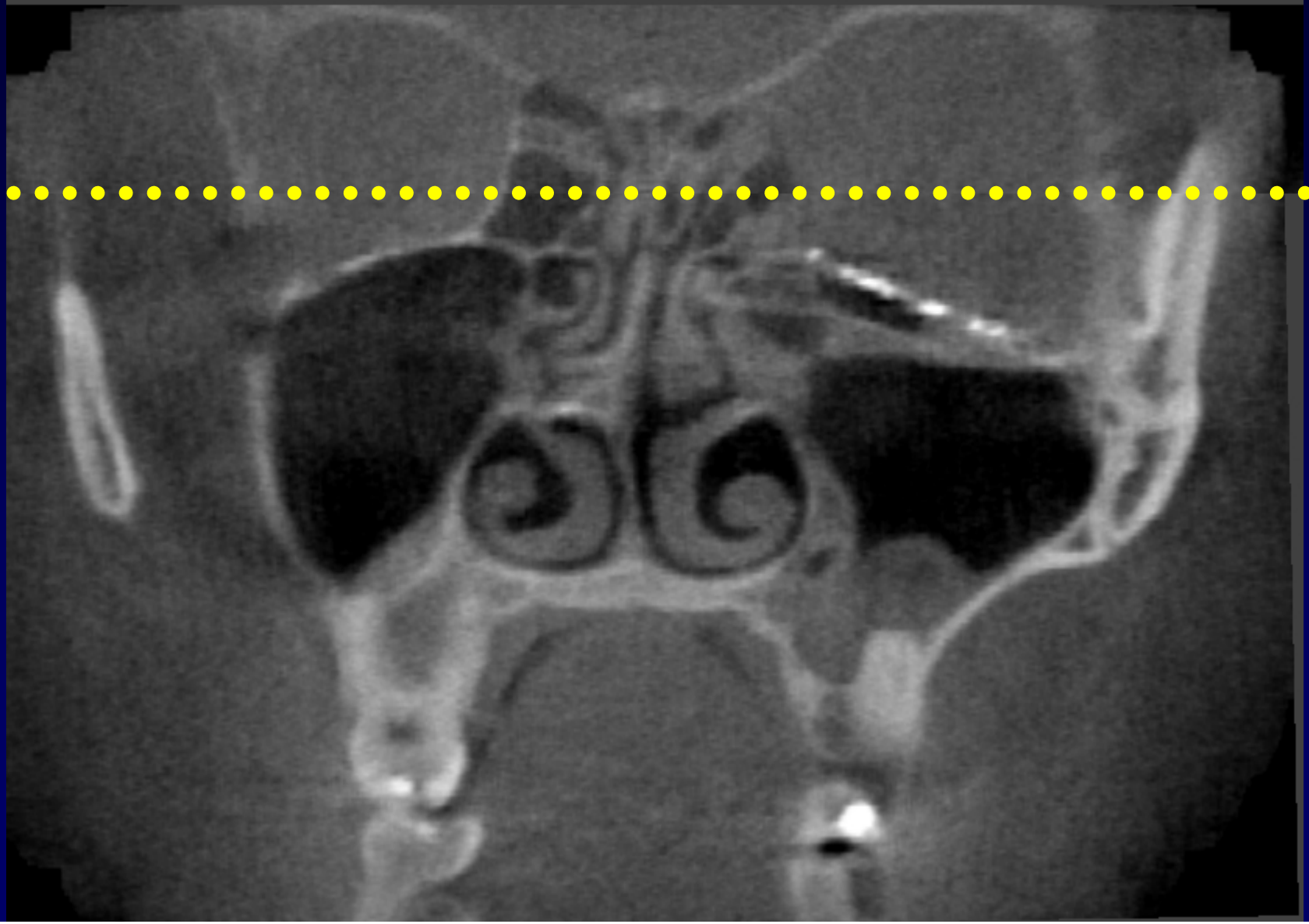

Digitale Volumentomographie

- 4-fach reduzierte Strahlendosis gegenüber CT
- Limitiertes Volumen (10,5 x 10,5 x 15 cm)
- keine suffiziente Weichteildarstellung

Indikationen

- Zahnärztliche Chirurgie
- Dentale Implantologie
- Traumatologie des Gesichtsschädels
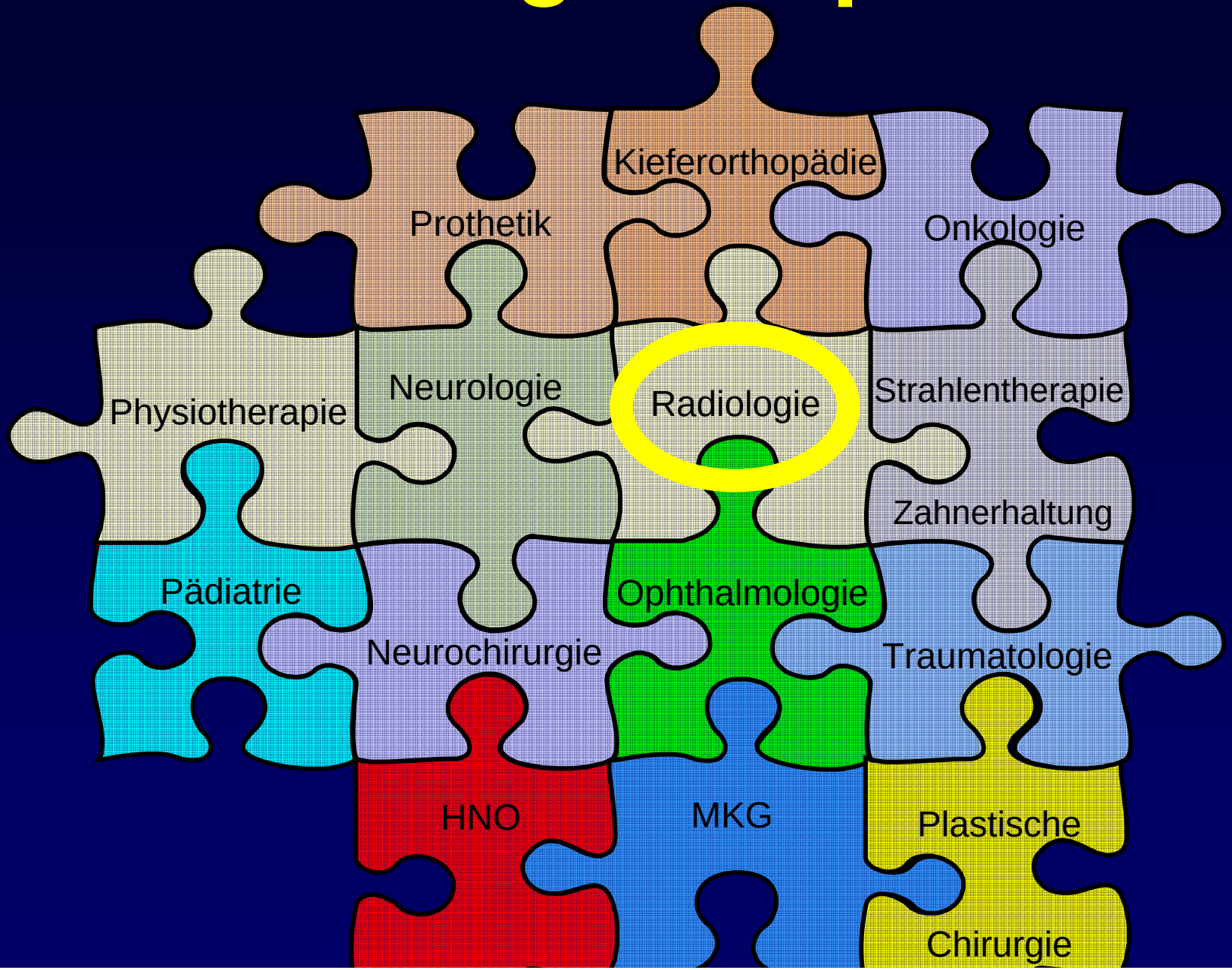
Erfolgsrezept?