MRE2.0: Hochauflösende mechanische Bildgebung

Ingolf Sack

Institut für Radiologie CCM

MRE: Magnetresonanzelastographie

- Elastizität,Viskosität, Struktur
- Druck, Porosität
- Was ist MRE1.0?
  - -Räumliche Auflösung
  - -Mikrostrukur
  - -Druck
- MRE2.0

Das Prinzip der MRE

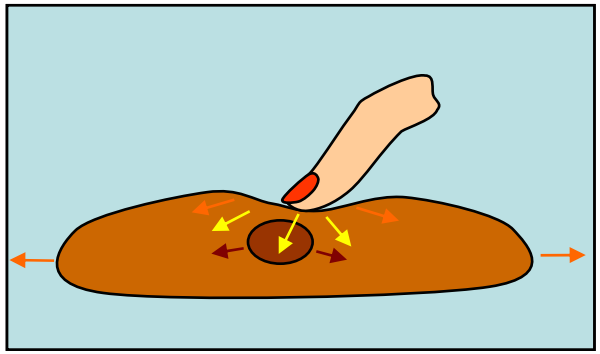

Scherdeformationen sind sensitiv
auf multiskalare viskoelastische Netzwerke



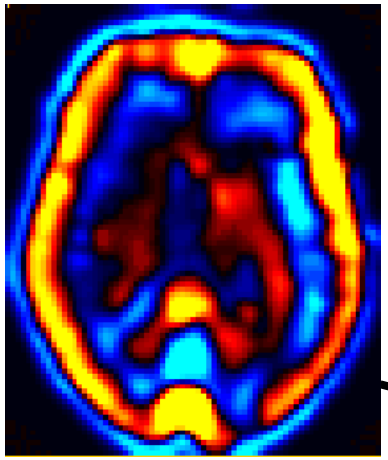

akustische Quelle

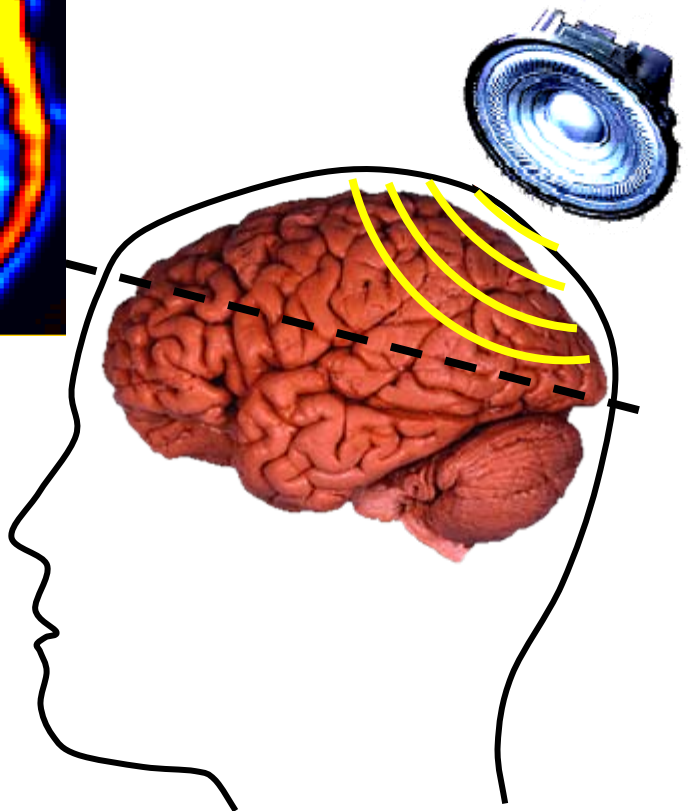

MRE ist sensitiv auf Struktur und Druck

Scherwellen: Viskoelastische Netzwerke



Kompressionswellen: Druck, Porosität, Filtration

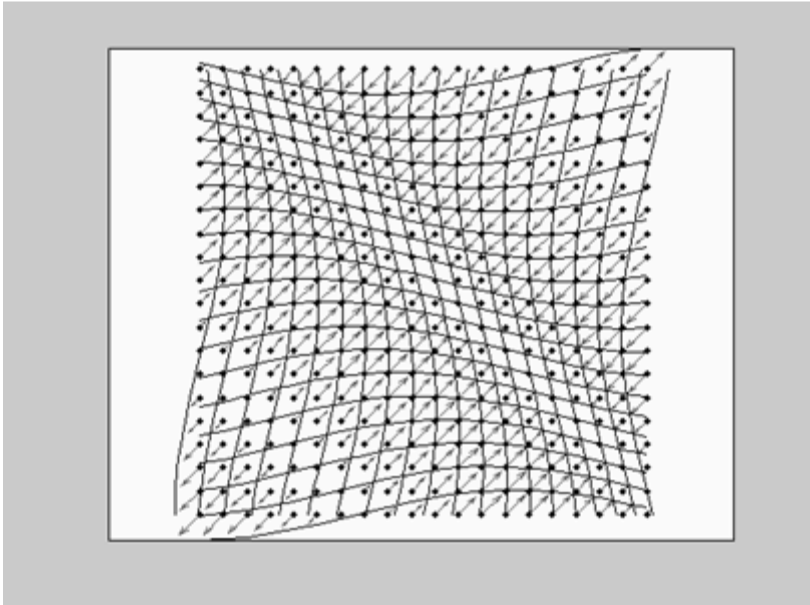

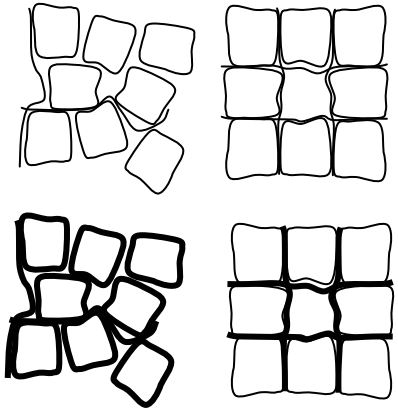

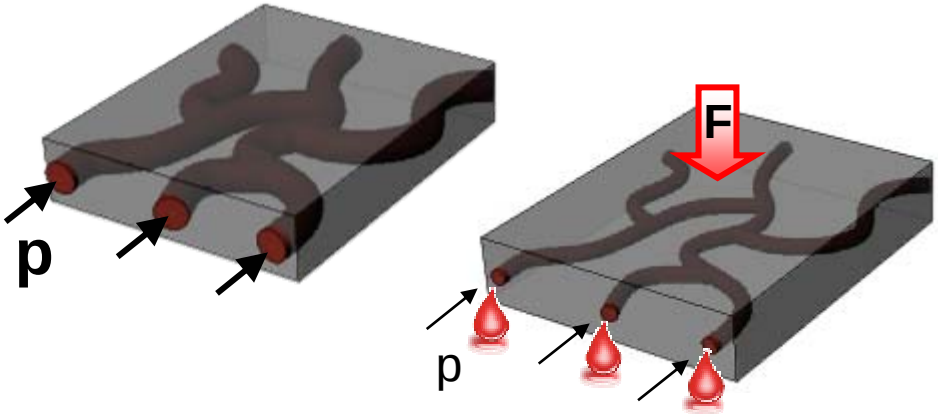

MRE1.0: Die Methode

Dr. R.Ehman
Mayo Clinic,
Rochester, MN

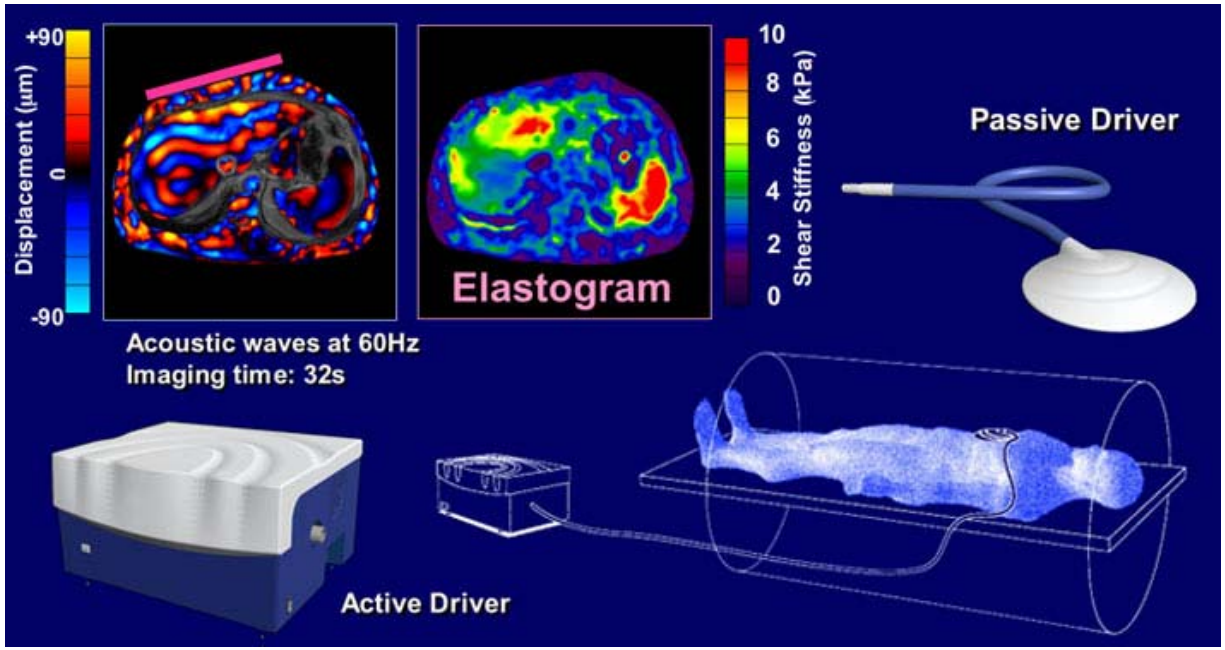

Charité

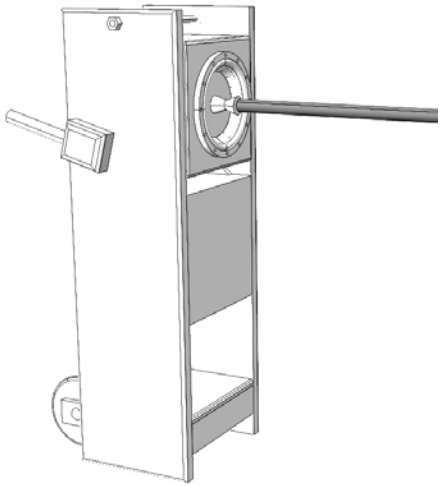

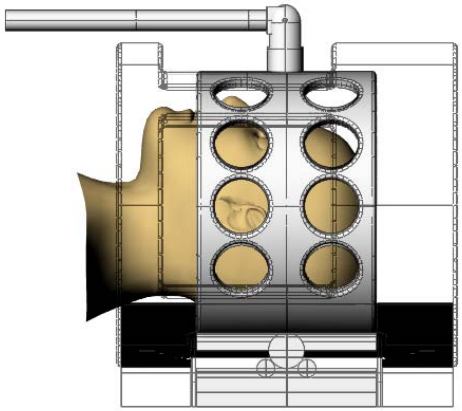

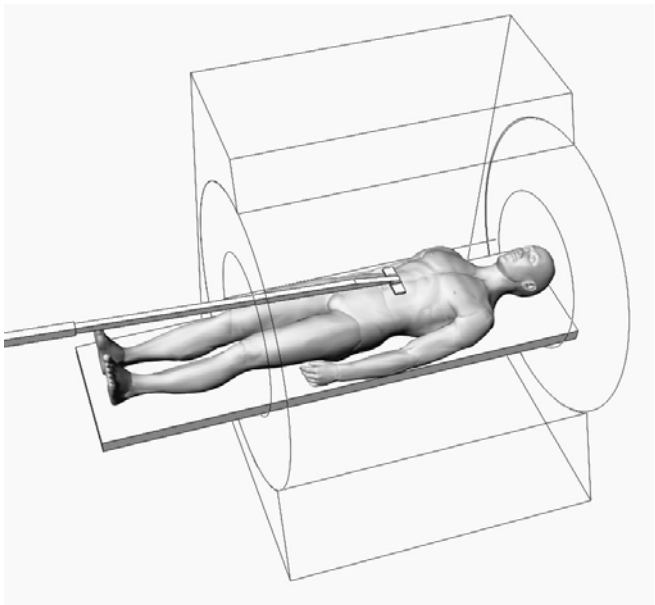

MRE1.0: Räumliche Auflösung

Hirntumor

Xu et al. Acta Radiol 2007;48(3):327-330.

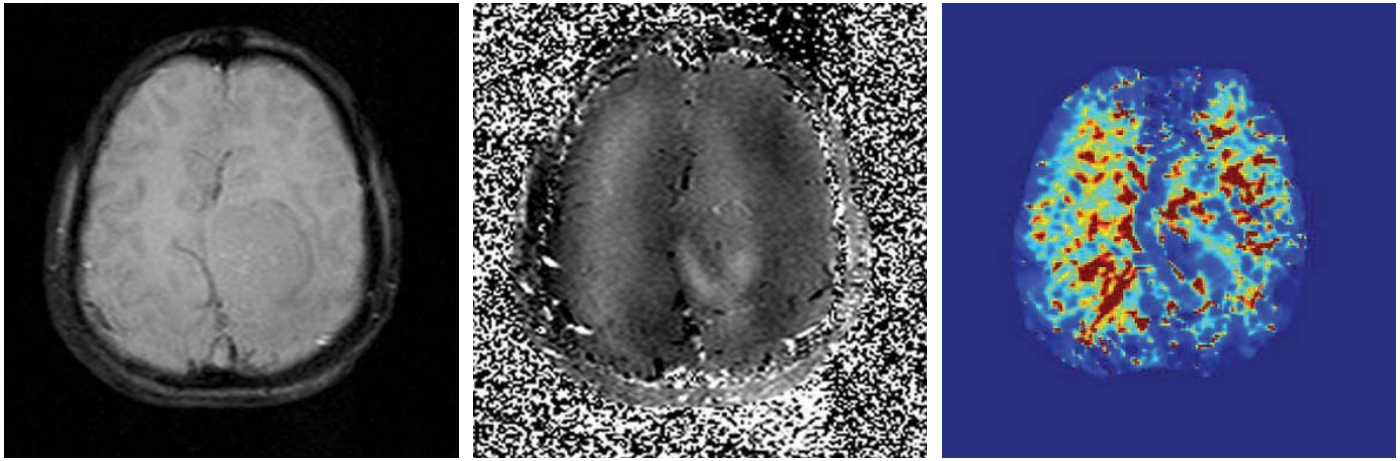

a1 a2 a3 a4

Leberfibrose

Dzyubak et al.
J Magn Reson Imaging 2013;
[Epub ahead of print].

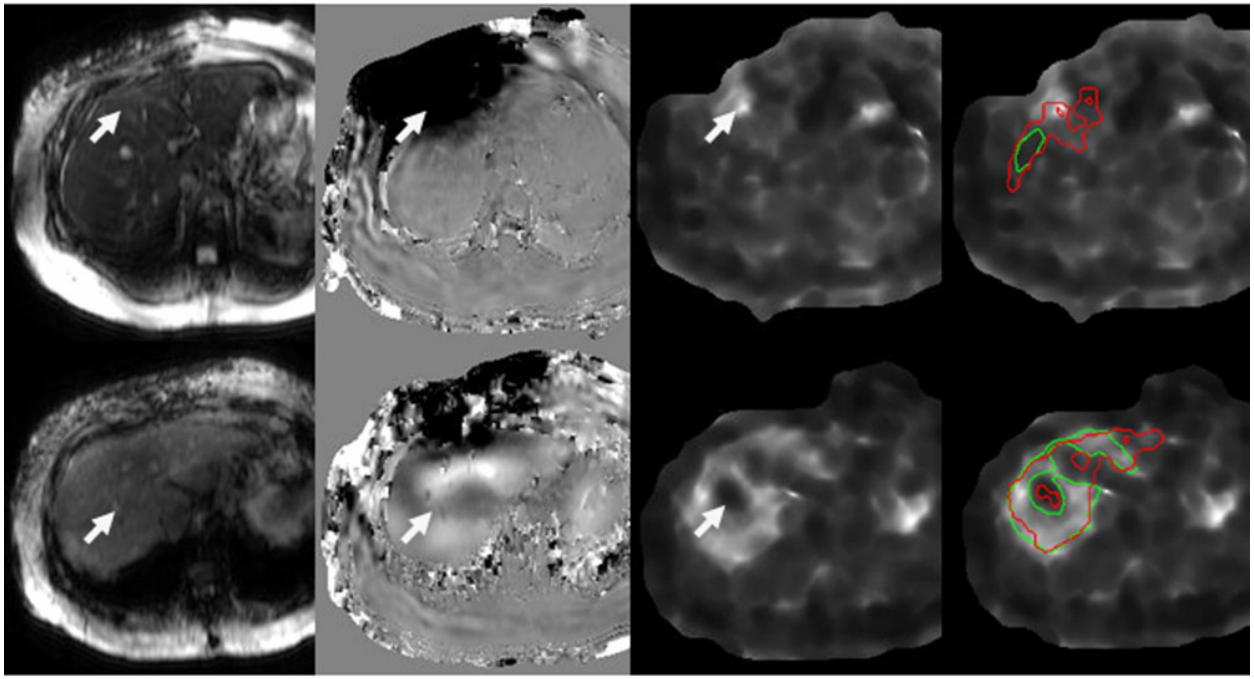

b1 b2 b3 b4

MRE1.0: Nichtinvasive Graduierung der Leberfibrose

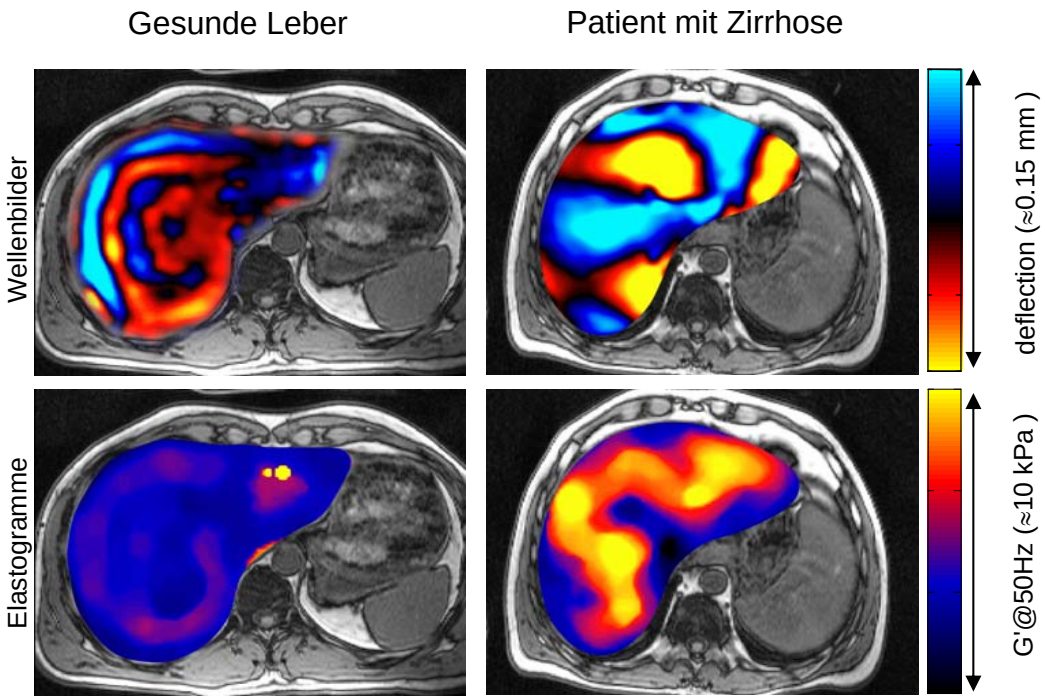

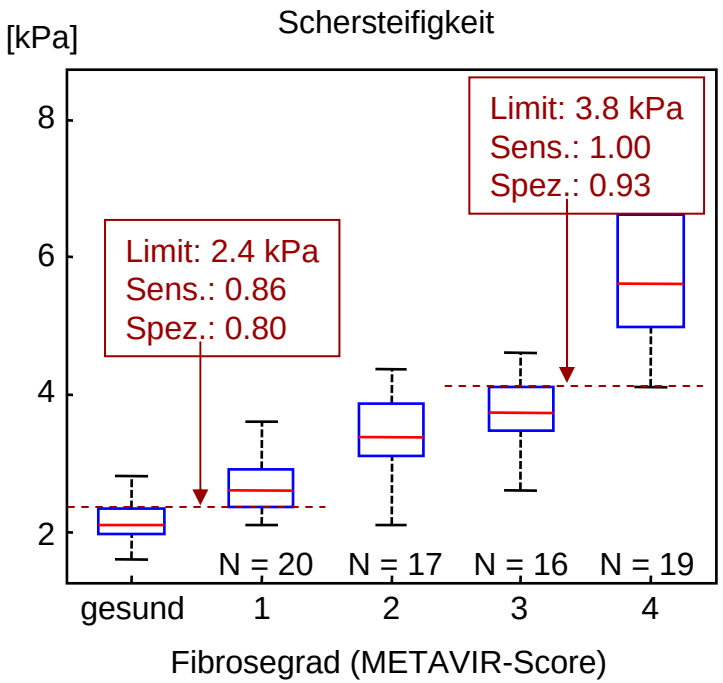

MRE1.0 der Leber: Bisher unübertroffene Genauigkeit bei der Fibrosegraduierung

Asbach et al. Radiology 2010

MRE1.0: Mehrfrequenz-MRE

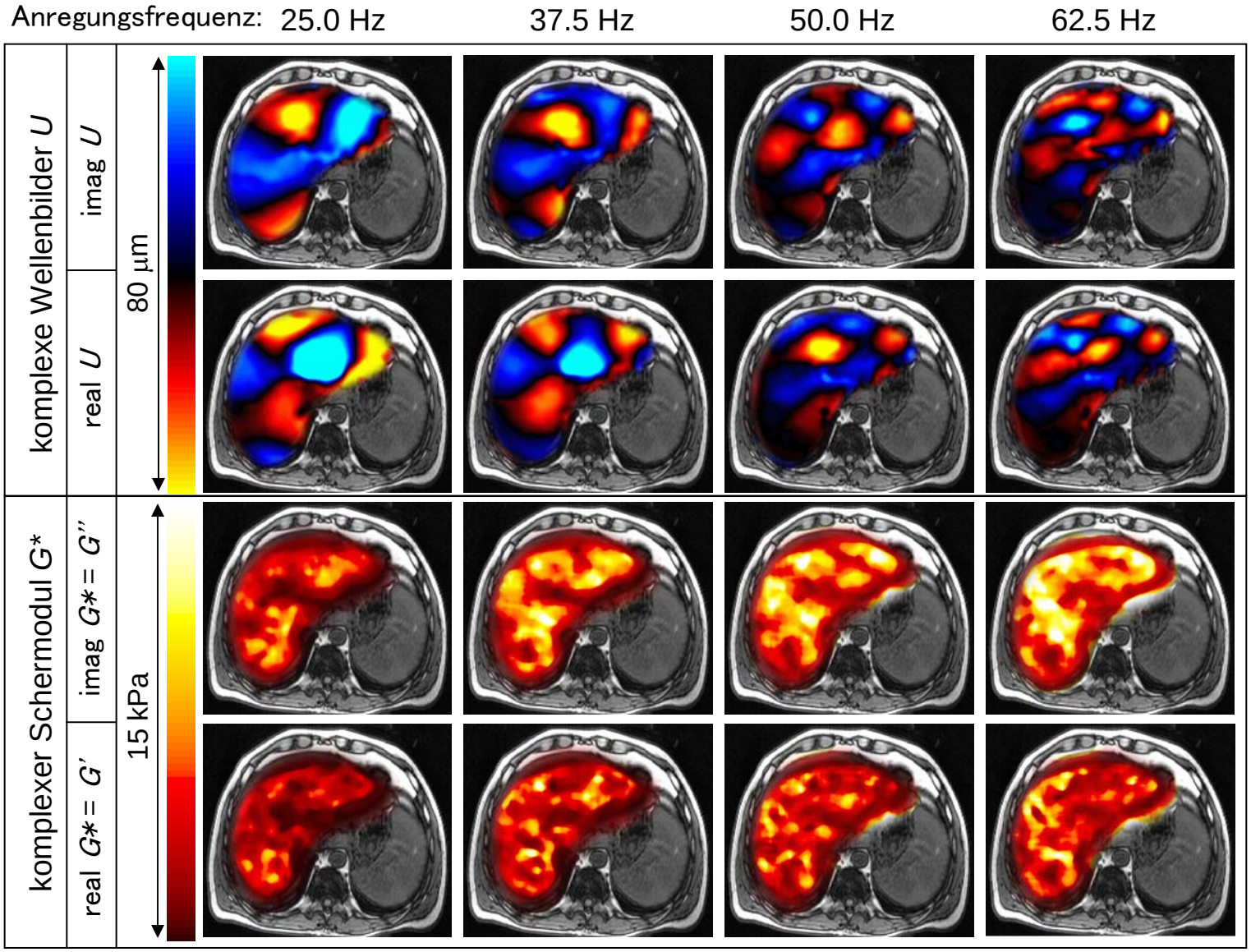

Asbach et al. Radiology 2010

Viskoelastizität und Struktur

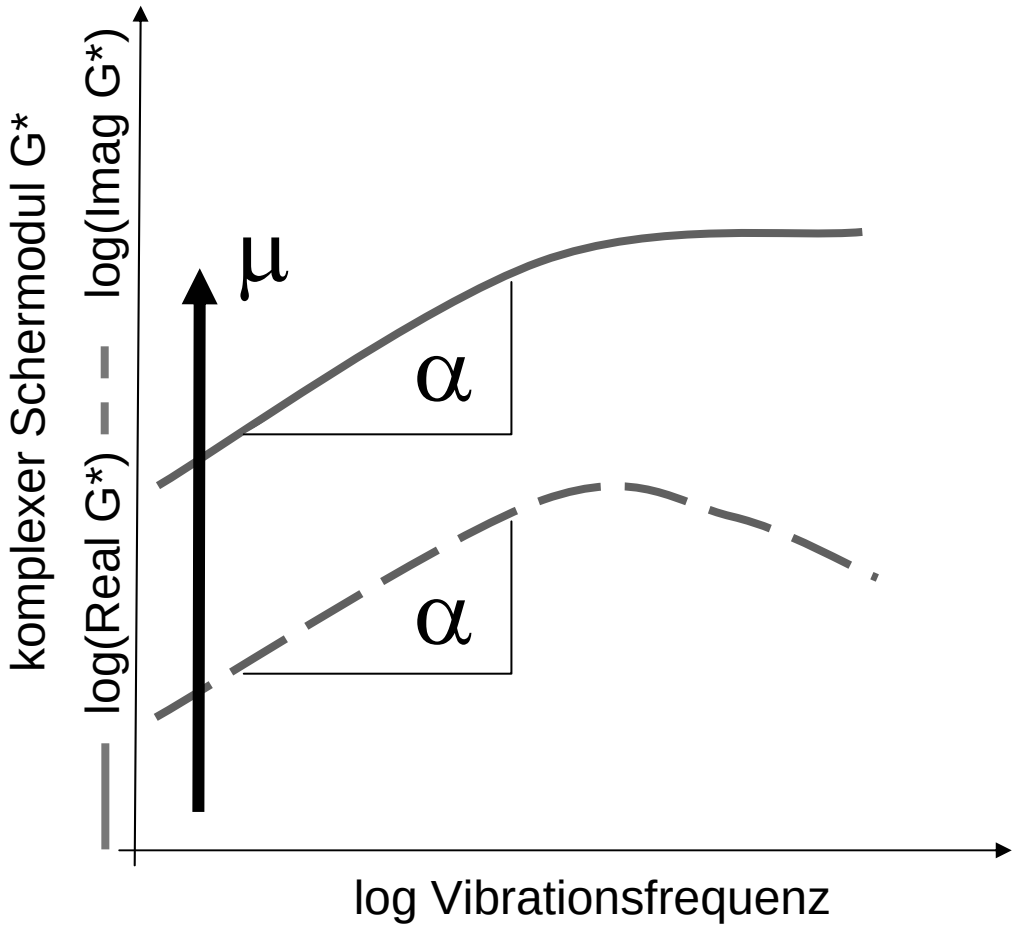

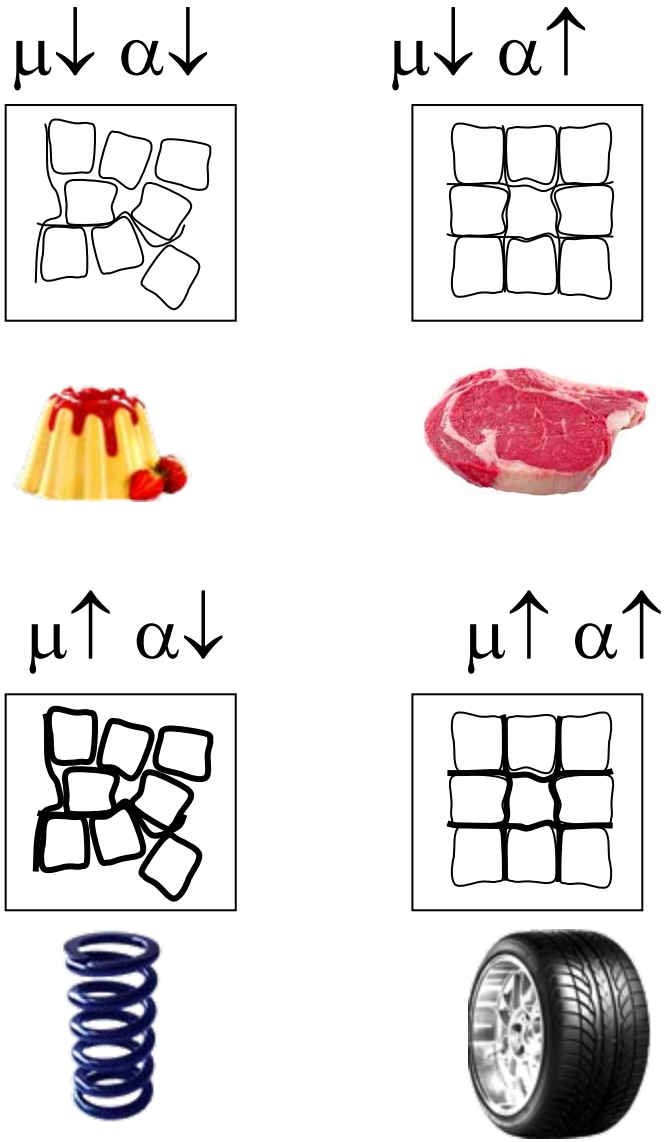

μ: Elastizität

α: Viskosität

MRE1.0: In vivo Viskoelastizität humaner Gewebe

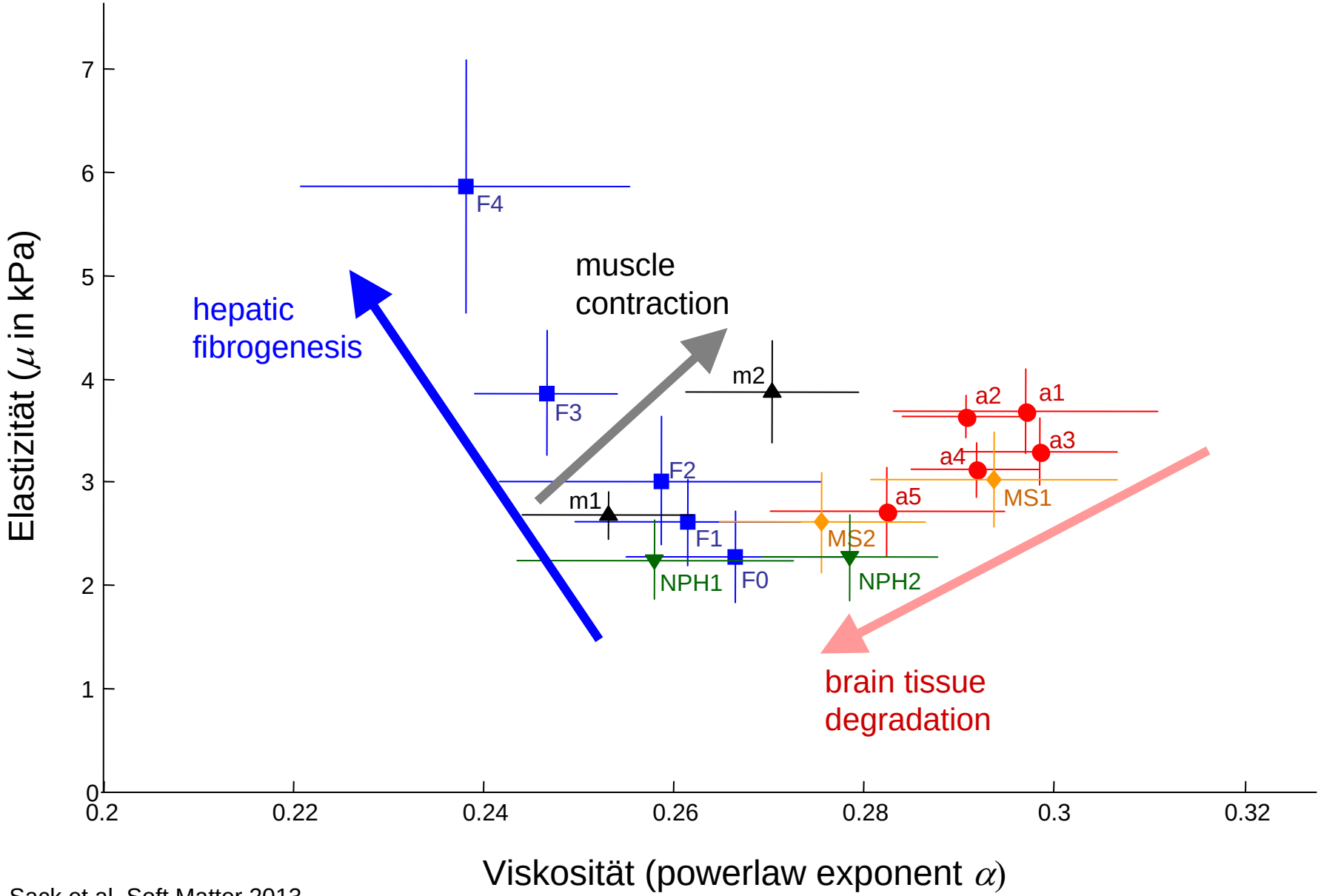

Sack et al. Soft Matter 2013

Struktursensitivität der MRE1.0

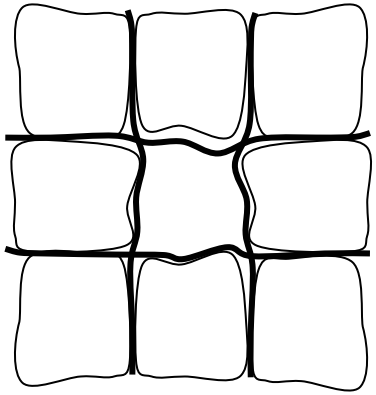

Muskel, entspannt $\xrightarrow{\mu\uparrow\ \alpha\uparrow}$ Muskel, angespannt

Klatt et al. Phys. Med. Biol. 2010

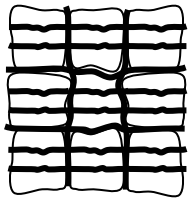

Leber, gesund $\xrightarrow{\mu\uparrow\ \alpha\rightarrow}$ Zirrhose

Asbach et al. Radiology 2010

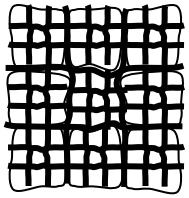

Hirn, jung $\xrightarrow{\mu\downarrow\ \alpha\rightarrow}$ Hirn, alt

Sack et al. Neuroimage 2009

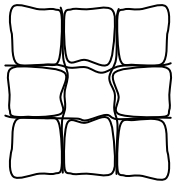

Hirn, gesund $\xrightarrow{\mu\downarrow\ \alpha\rightarrow}$ MS, mild

Wuerfel et al. Neuroimage 2010

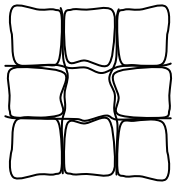

Hirn, gesund $\xrightarrow{\mu\downarrow\ \alpha\downarrow}$ MS, chronisch

Streitberger et al. PlosOne

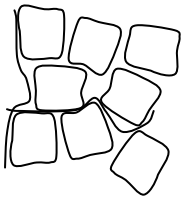

Viskoelastizität bei Normaldruckhydrozephalus (NPH)

healthy

$\mu\downarrow\ \alpha\downarrow$

NPH

NPH vor Shunt

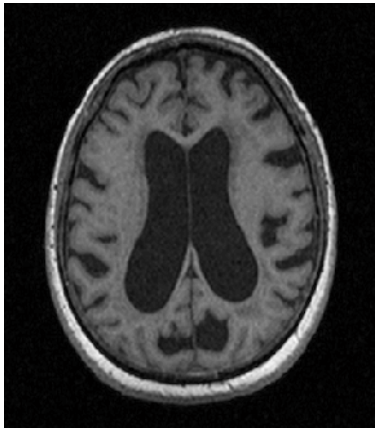

$\mu\leftrightarrow\ \alpha\uparrow$

3 months
post shunt

NPH nach Shunt

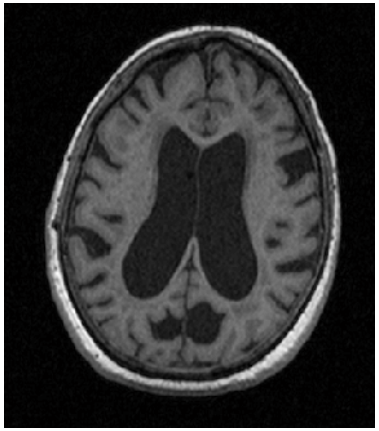

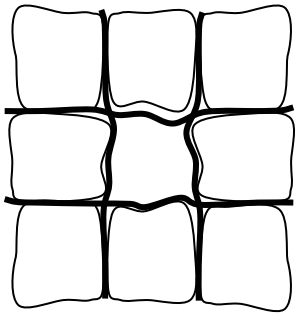

neuronale
Degeneration

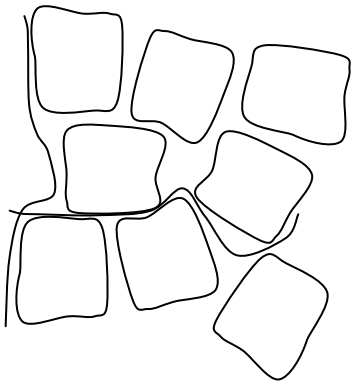

Reorientierung des
neuronalen Netzwerks

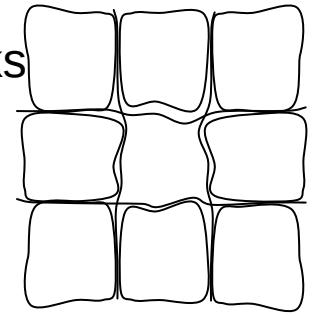

Streitberger et al. NMR Biomed. 2010
Freimann et al. Neuroradiol. 2011

pressure?

3D MRE

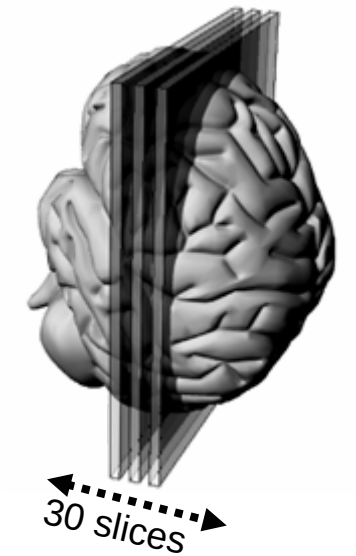

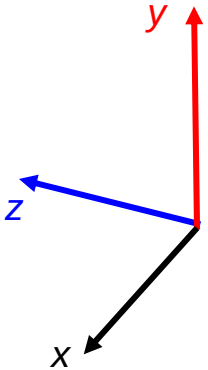

3 Komponenten



8 Zeitschritte

z

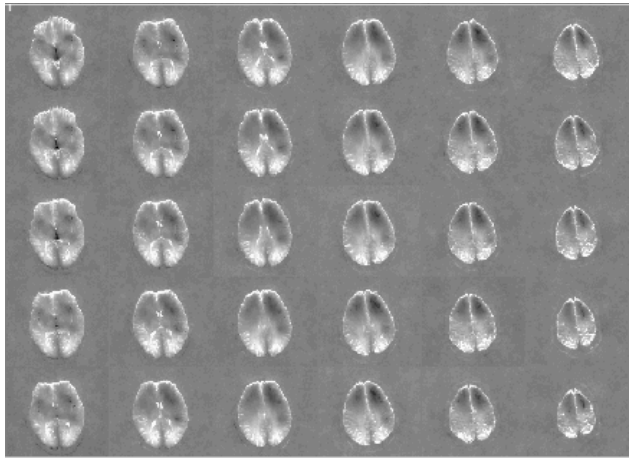

x

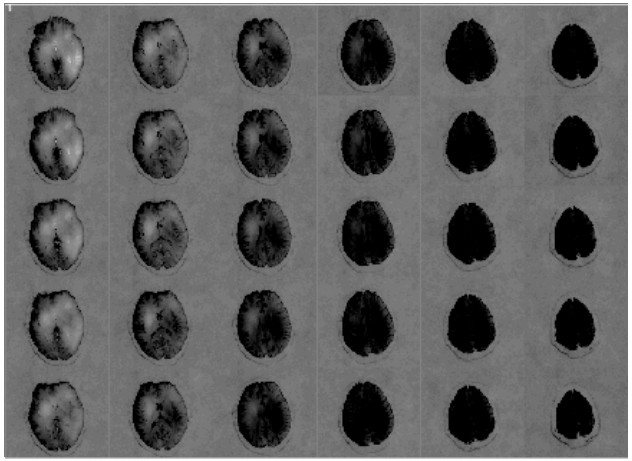

y

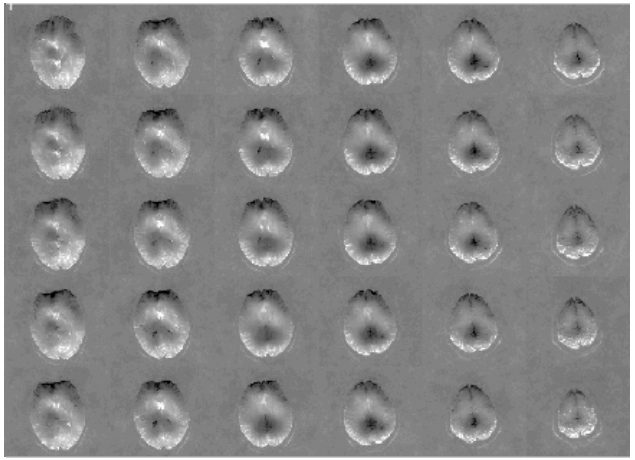

Gesamtuntersuchungszeit pro Frequenz (720 Bilder): ≈3,5 min

MRE1.0: Kompressions-MRE im Gehirn

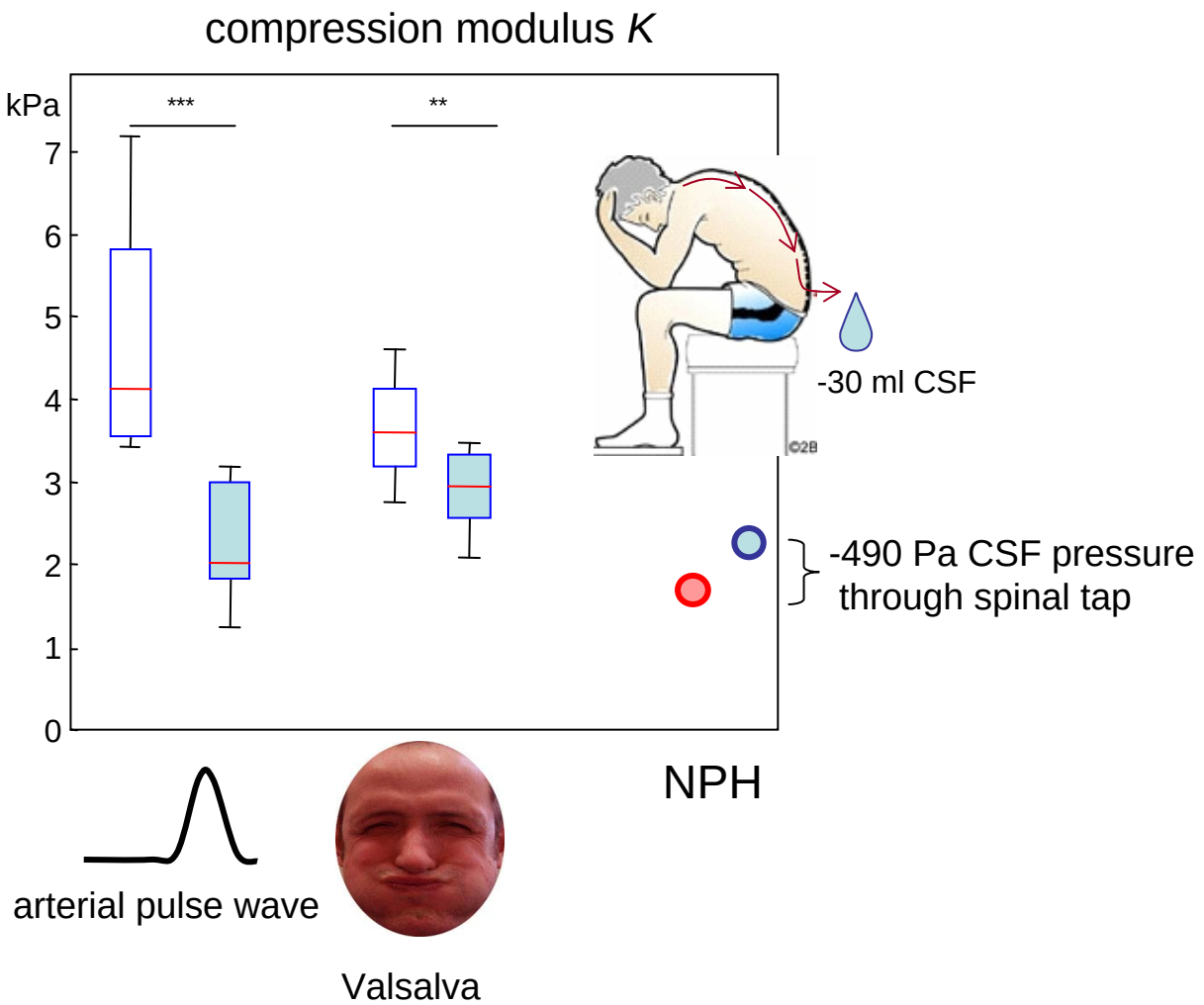

$|K| = 570$ Pa

Hirsch et al. MRM 2013

MRE1.0: Intrahepatischer Druck

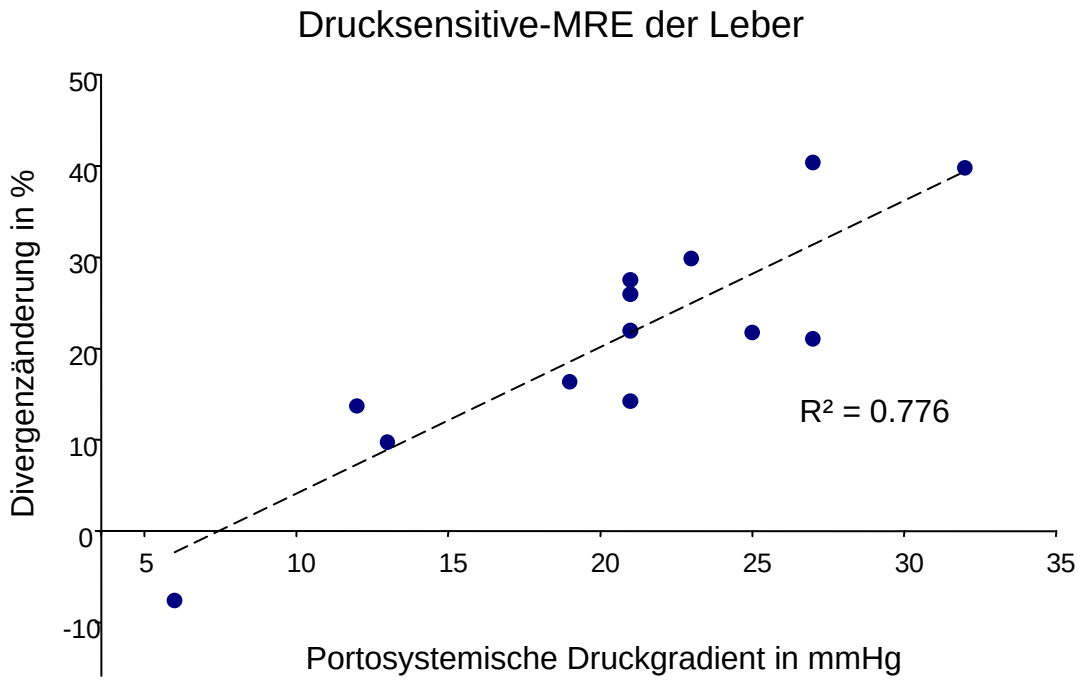

Druck-MRE sensitiv gegenüber Reduktion
des intrahepatischen Druckgradienten aufgrund einer TIPS-Anlage

Hirsch et. al J. Magn. Reson. Med. 2013

MRE2.0

MRE2.0: Nichtmagnetisches Schwingungssystem

Bewegungswandler

Überträger

Leber-MRE



Hirn-MRE

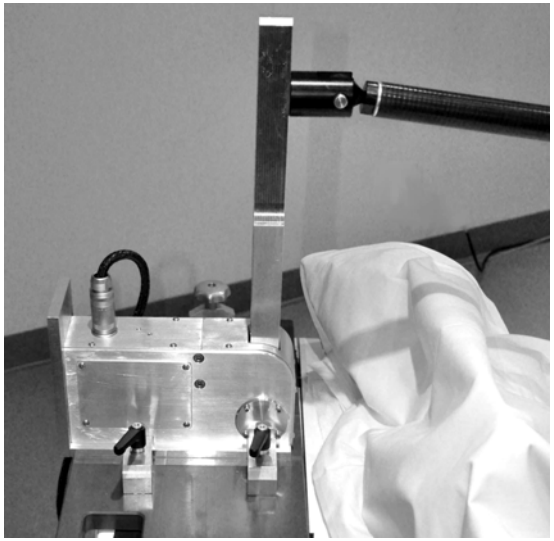

MRE2.0: 3DMMRE (3D-Mehrfrequenz-MRE)

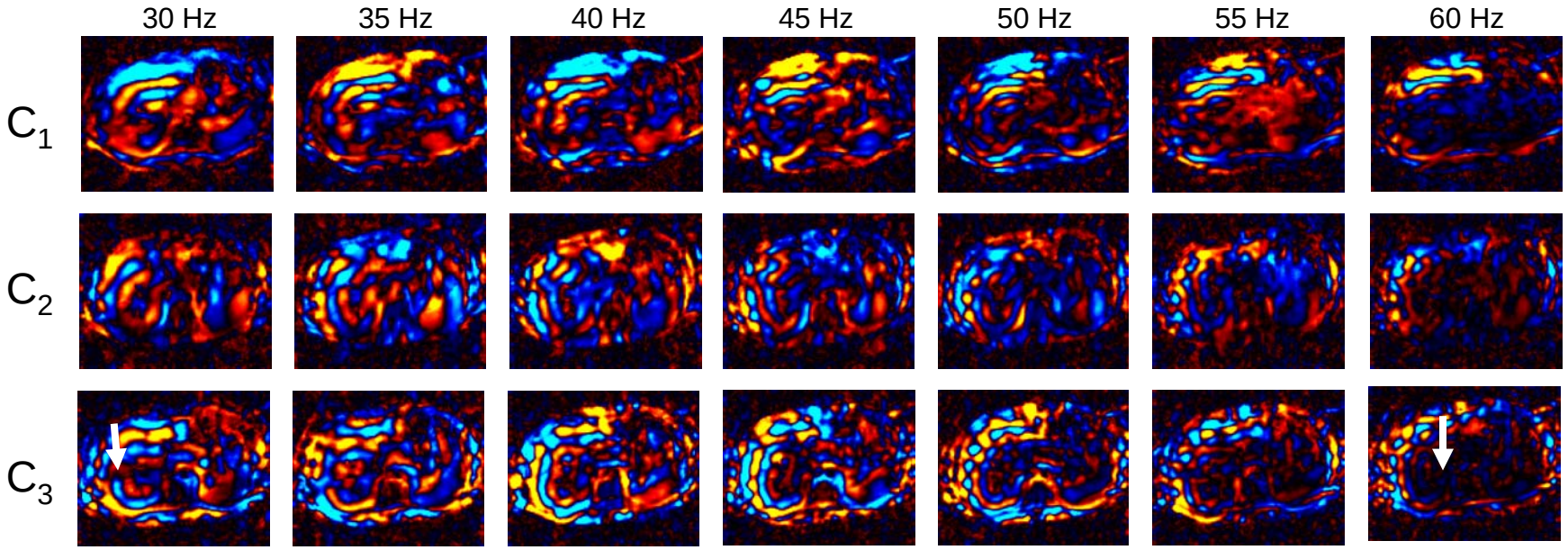

7 Frequenzen, 3-Feld-Komponenten, 8 Zeitschritte, 10 Schichten in ~10min Messzeit

Guo et al. RöFo 2013, in print

MRE2.0: MDEVI (Multifrequency dual elasto-visco inversion)

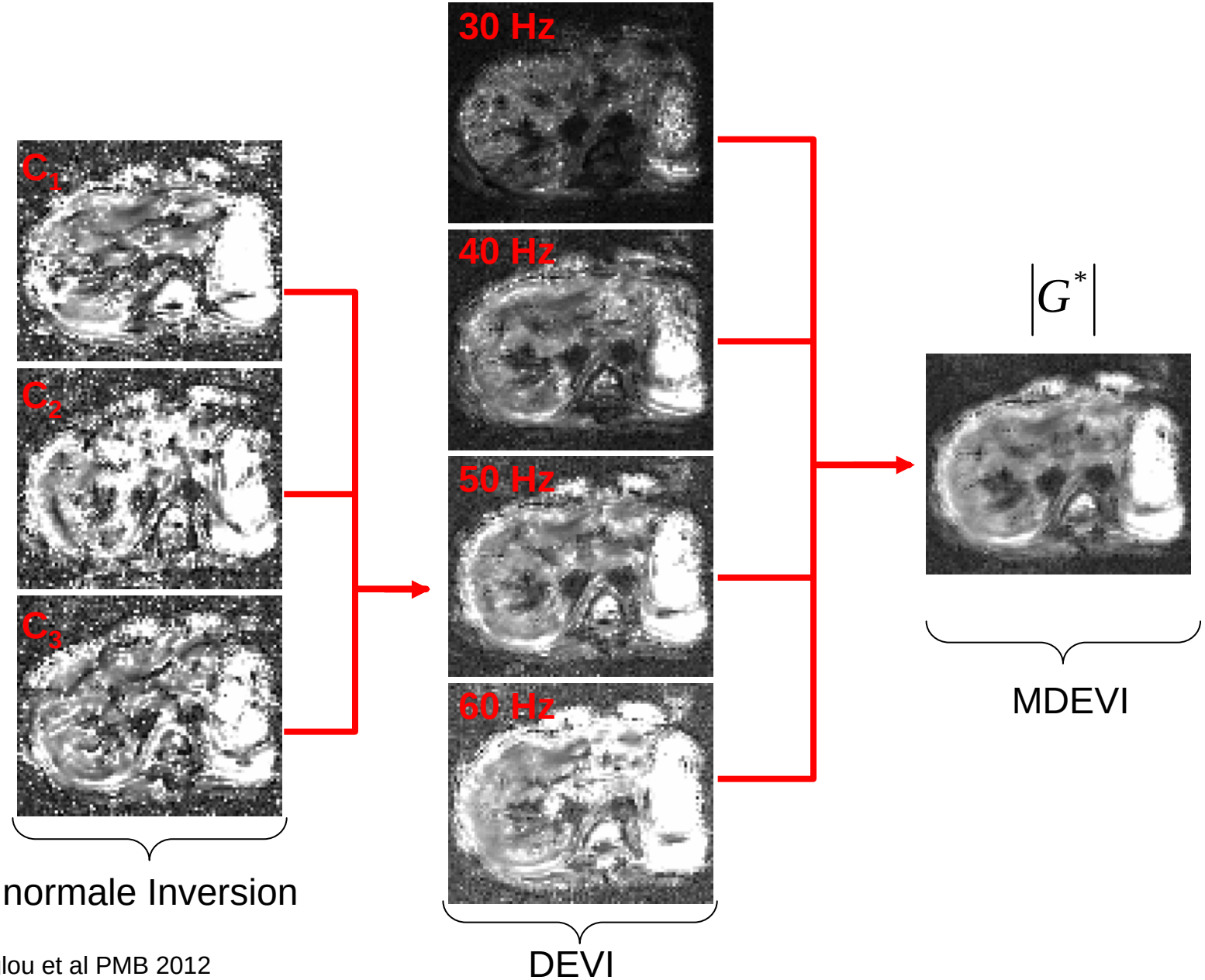

Papazoglou et al PMB 2012

MRE2.0: 3DMMRE mit MDEVI der Leber

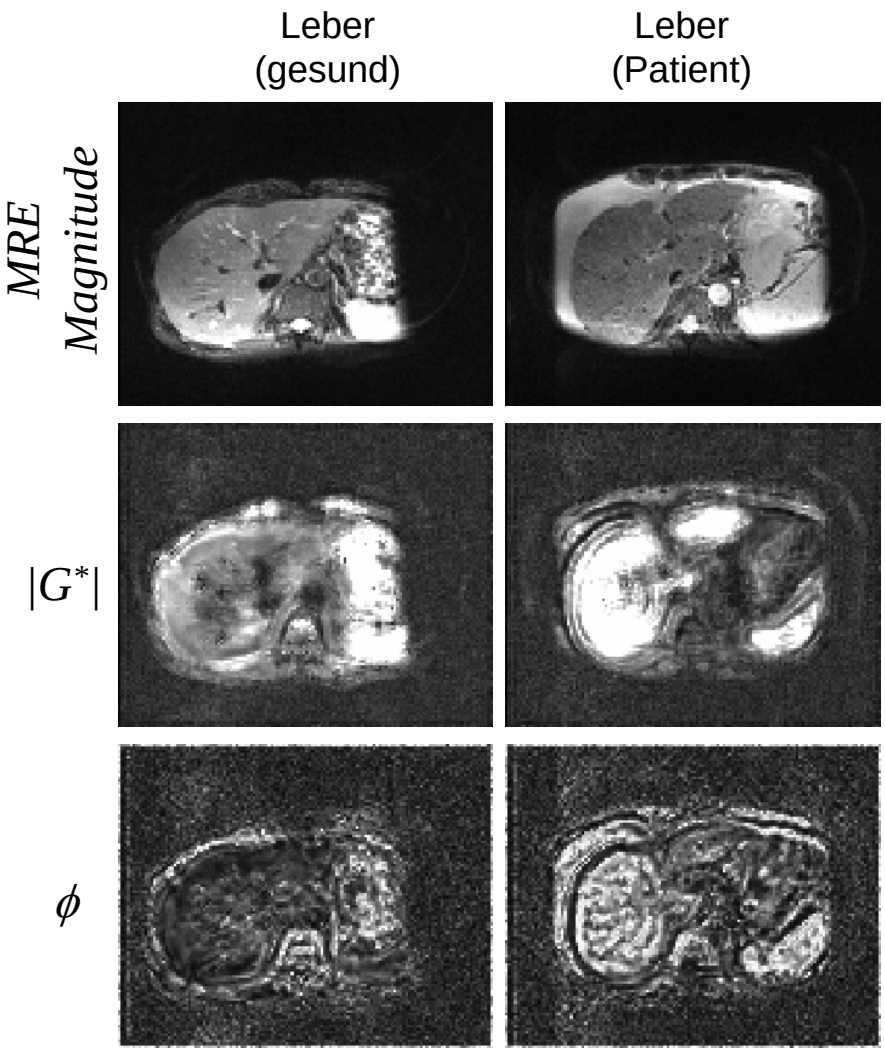

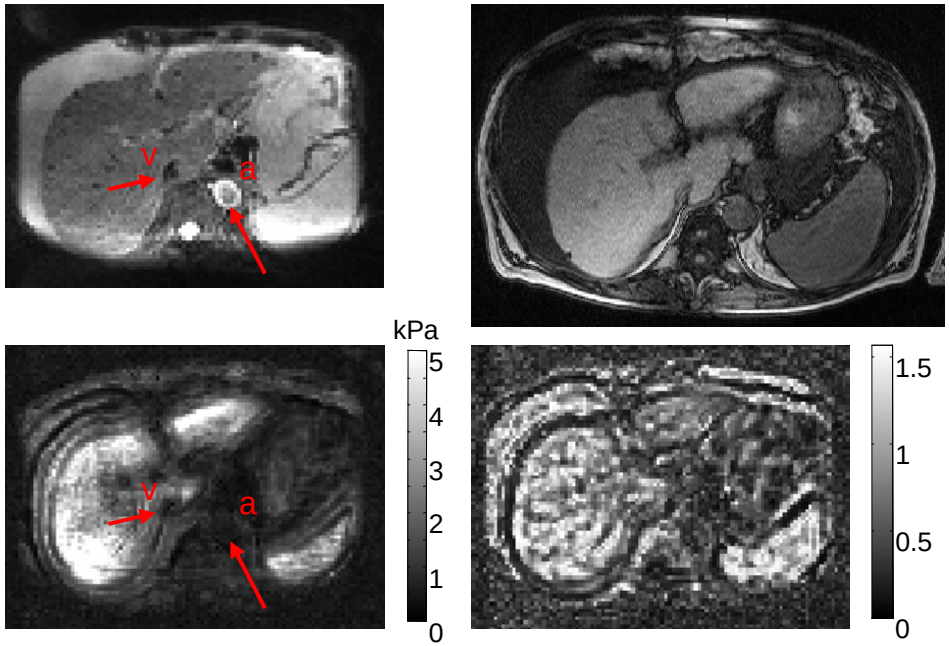

Hirsch et al MRM 2013

Abdominale MRE2.0

MRE Magnitude | $|G^*|$ | ϕ

Leber / Milz

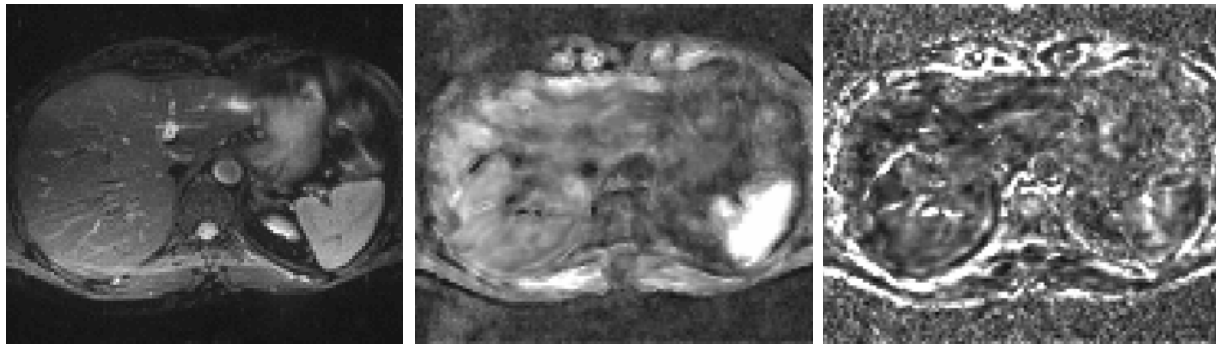

Leber / Nieren

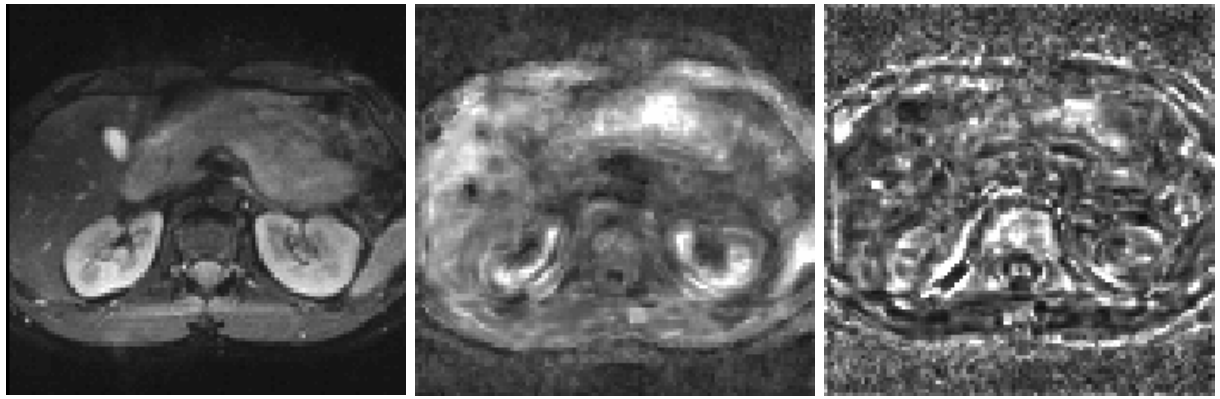

$|K|$

Bandscheibe

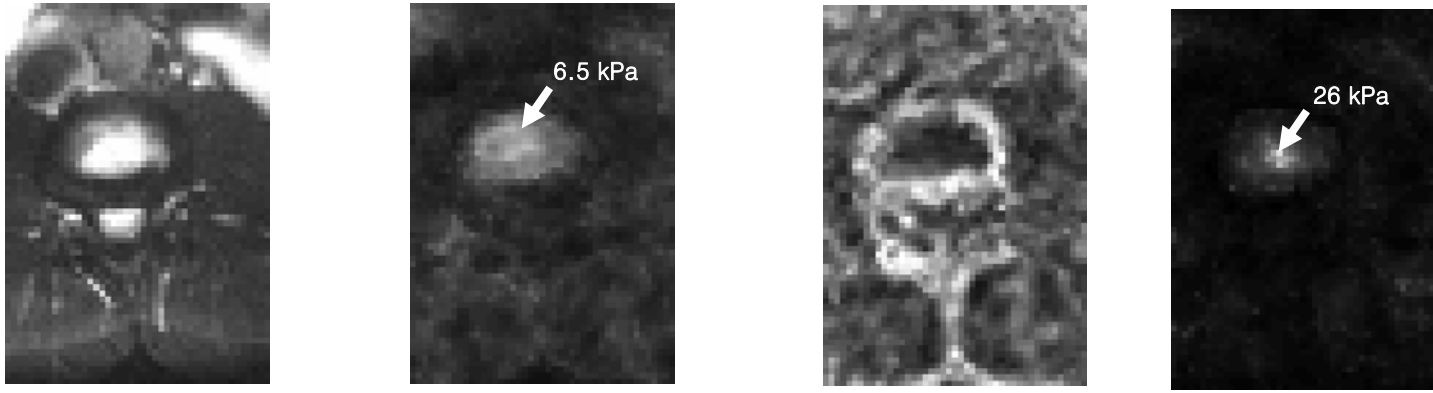

MRE2.0: HCC

MRT (T1, T2)

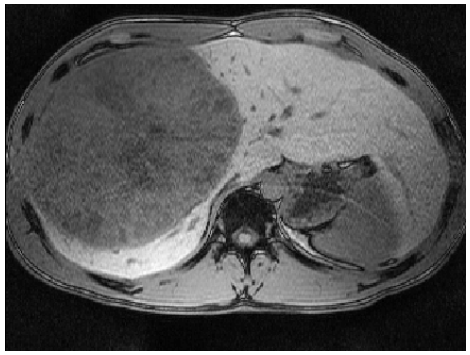

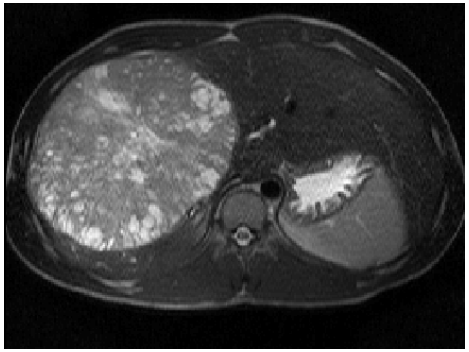

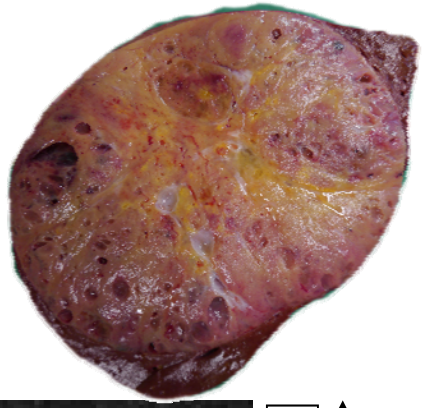

MRE (|G*|, ϕ)

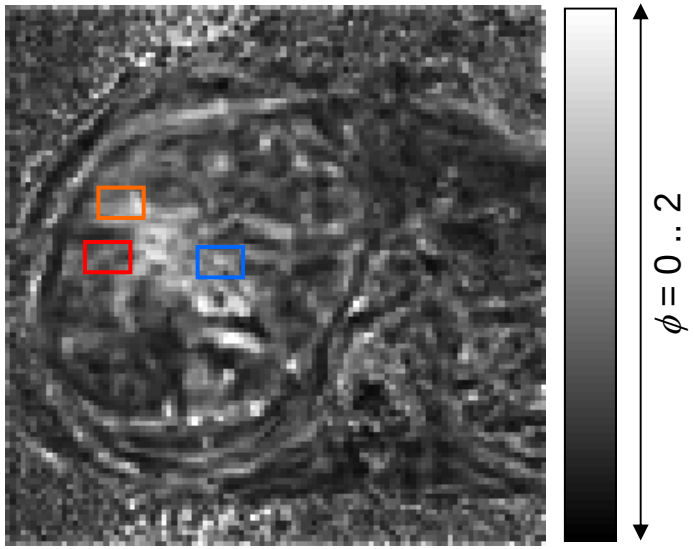

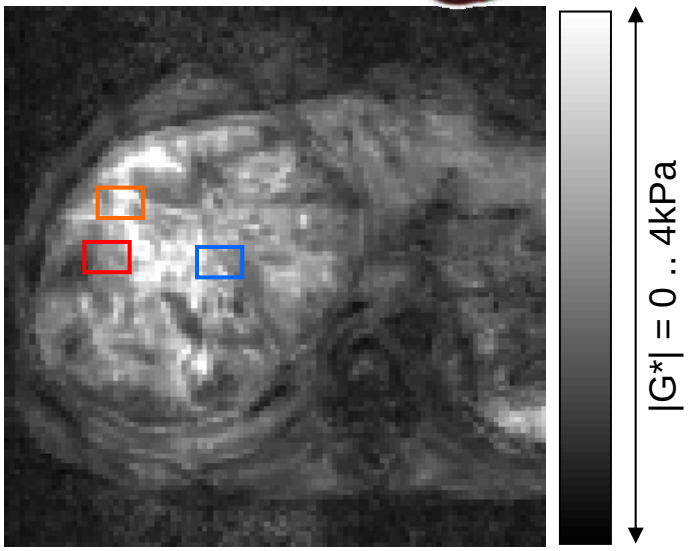

histo

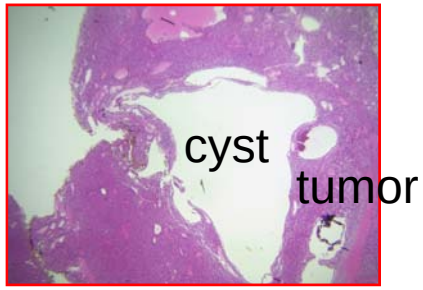

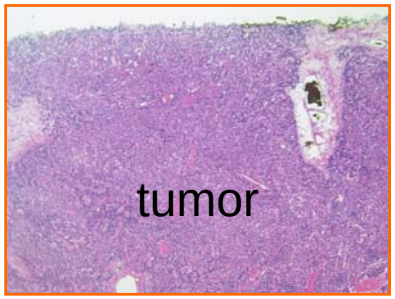

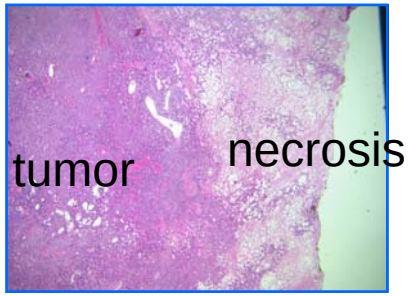

MRE2.0: Hirn

Atlas der Hirnmechanik:
(25 gesunde Freiwillige)

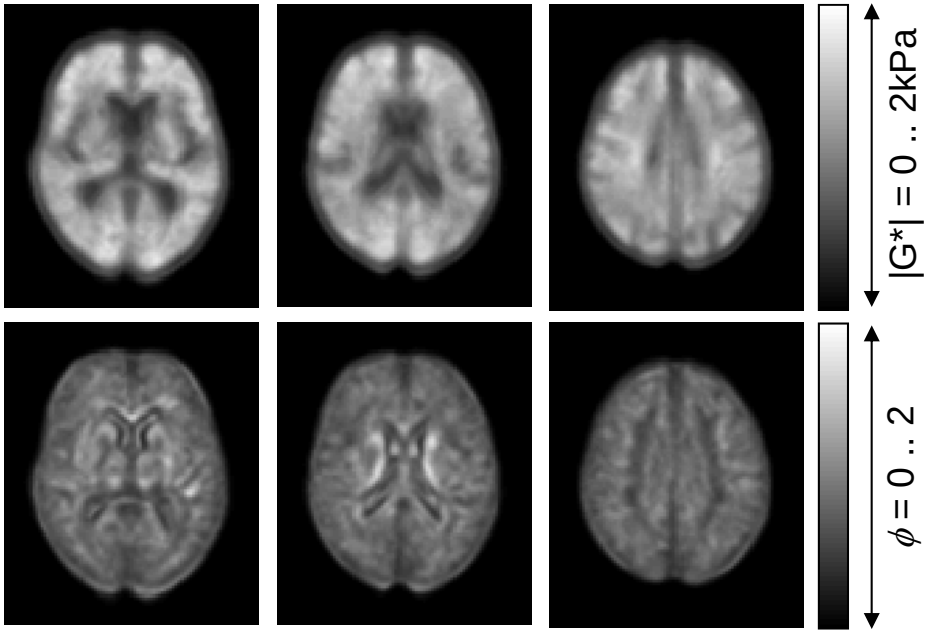

Hirn
(Glioblastom)

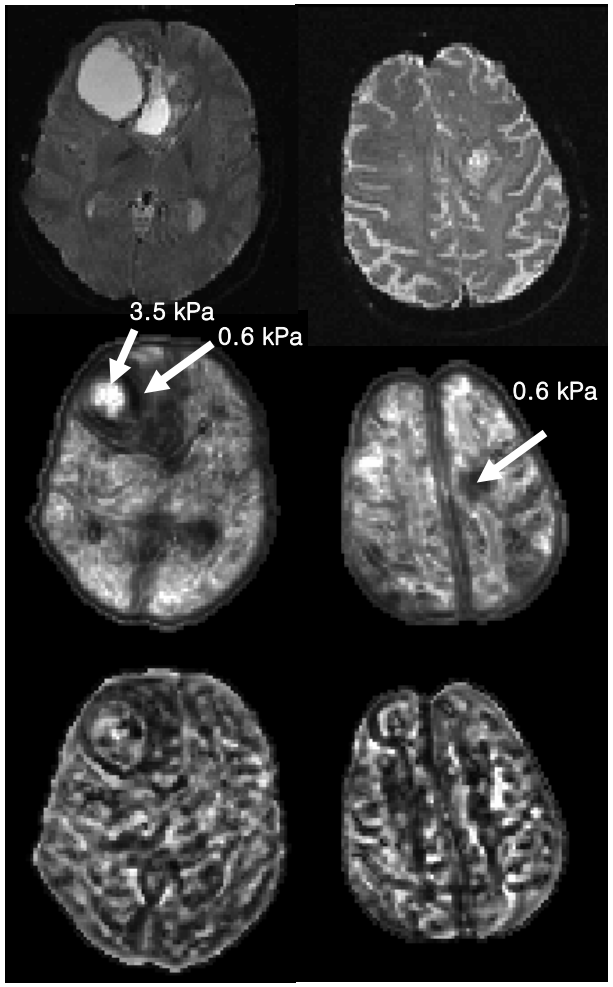

MRE2.0 at 7T: Hirn

MRE magnitude

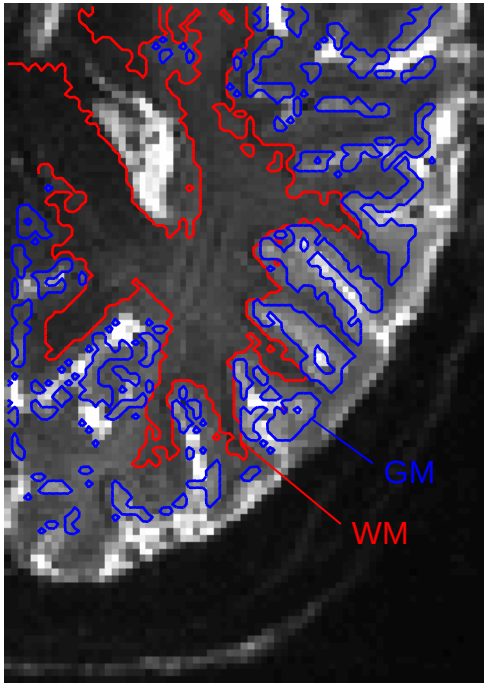

$|G^*|$

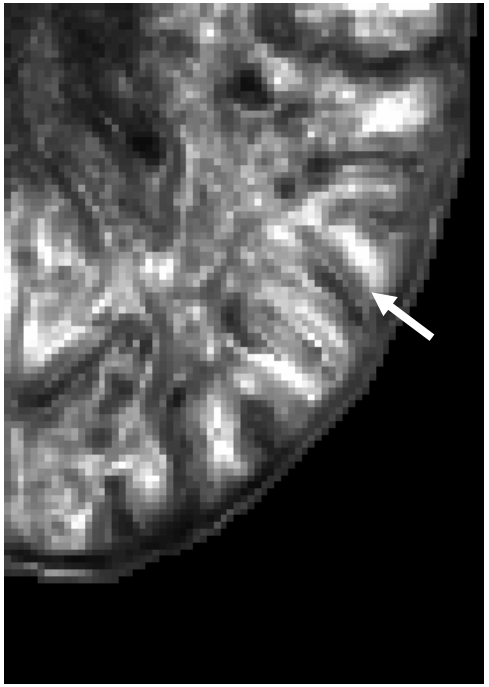

ϕ

Auflösung 1 x 1 x 1 mm³
erstmalige Differenzierung von grauer und weißer Substanz!

Zusammenfassung

MRE1.0: Gemittelte mechanische Kenngrößen

-drucksensitiv

-struktursensitiv

MRE2.0: ortsaufgelöste mechanische Kenngrößen

regional aufgelöste Druck- und Struktursensitivität

potenziell viel höhere diagnostische Genauigkeit!

die AG Elastographie der Charité

PD Jürgen Braun

Dipl. Phys. Andreas Fehlner

Dipl. Phys. Sebastian Hirsch

Dipl. Phys. Heiko Tzschätzsch

Dr. Jing Guo

Dr. Sebastian Papazoglou

clinical Radiologists involved in MRE:

PD Thomas Elgeti

PD Patrick Asbach

PD Thomas Kroencke

Dr. Michael Scheel

Prof. Thomas Fischer