PHILIPS

2000: 3 T

Technik und Trends der MRT: "Wozu braucht man 3T?"



1980: 0.15 T

Bernhard Schnackenburg
Senior Clinical Scientist
22. Juni 2013

- Einleitung
- 3T vs 1.5T
- Technische Entwicklungen
- Klinische Beispiele
- Zukünftige Entwicklungen

Whole body MR

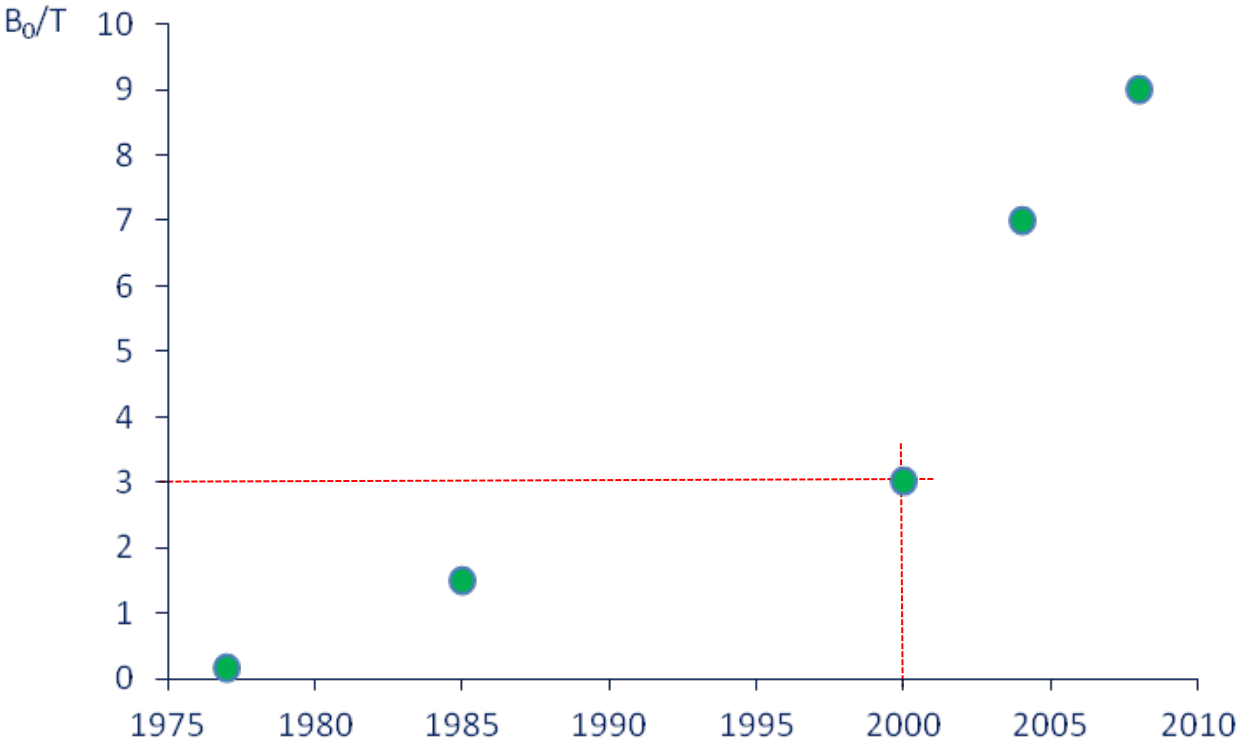

Market trend (2002 – 2008)

The move to 3.0T is growing

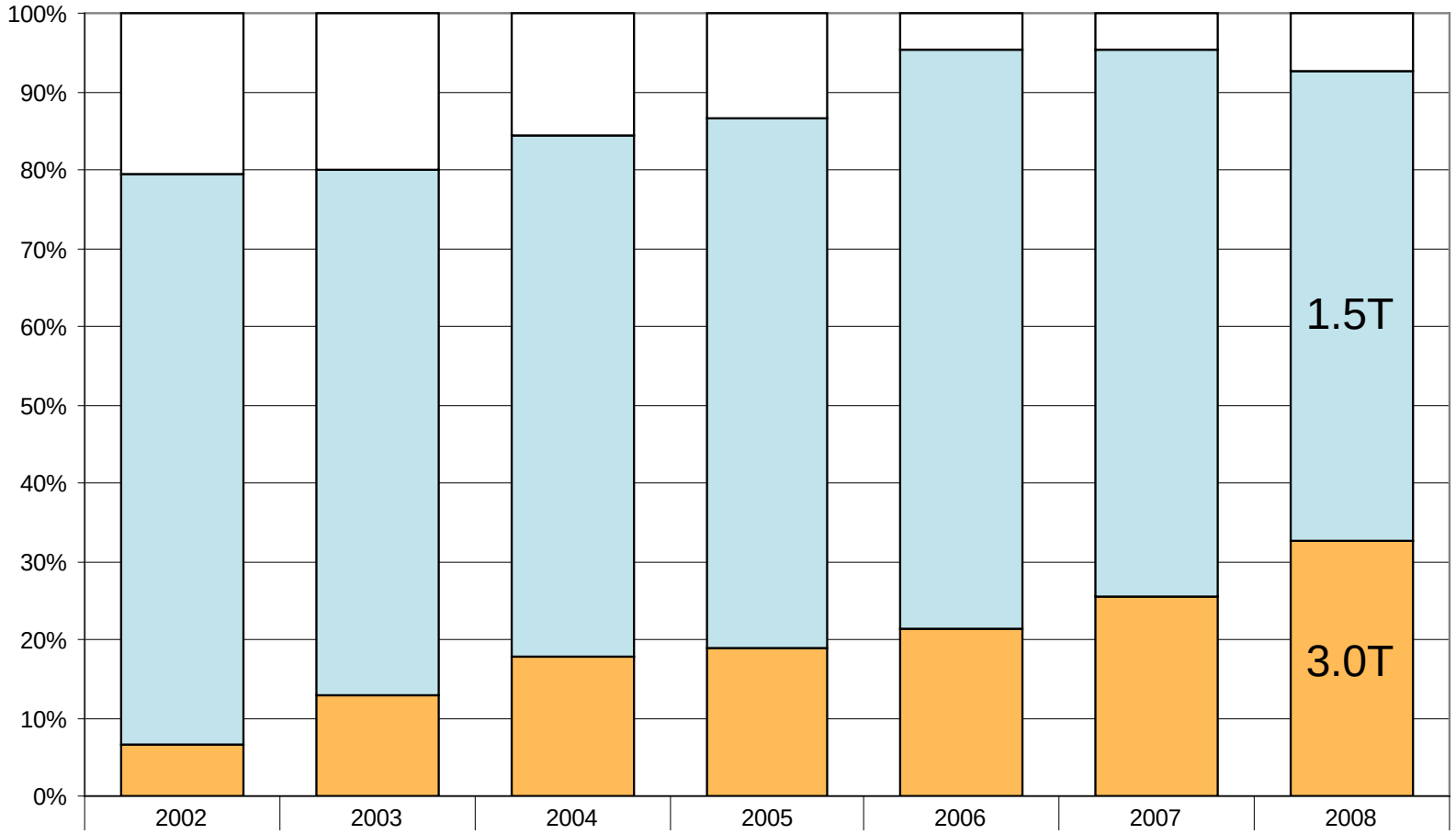

Source: NEMA, MDBuyline, IMV

PHILIPS

3T vs. 1.5T

Parameter changes 3T vs. 1.5T

pro

SNR ↑ (factor 2)

Chemical shift ↑ (spectroscopy, fat suppr.)

T1 ↑ (storage of M_z; e. g. inflow angio)

Δ T2* ↑ (BOLD)

cons

SAR $\propto \omega^2$ (i.e. factor 4 !) ↑ ↑

Chemical shift artefact ↑

T1 ↑ (TR ↑)

T2* ↓

Suszeptibility effects ↑

B_1- inhomogeneities ↑

Magnetohydrodynamic (MHD) artefakt ↑

SAR = specific absorbtion rate

PHILIPS

3T pro

SNR ↑

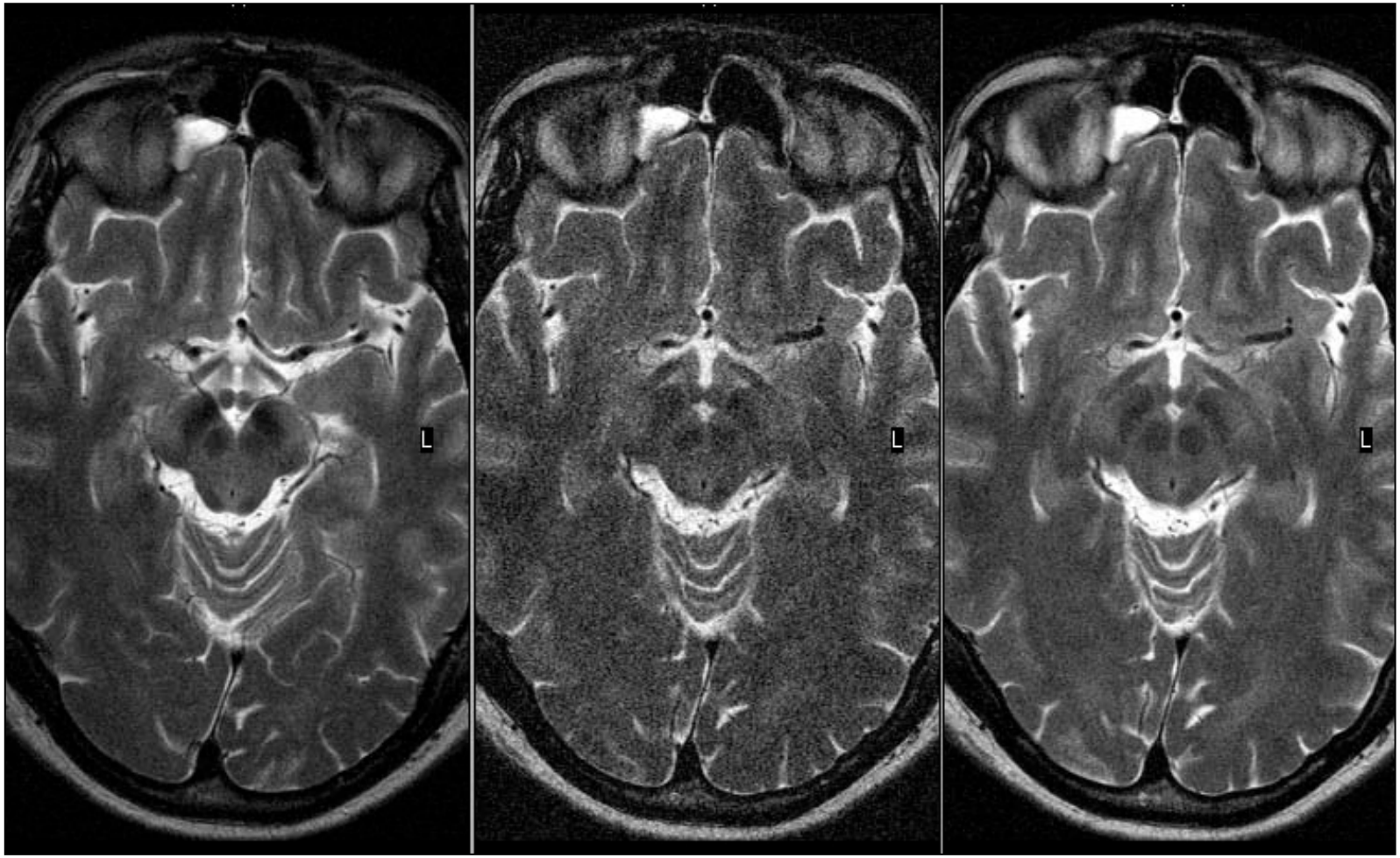

3.0T	1.5T	1.5T
NSA=1	NSA=1	NSA=4

PHILIPS

3T pro

Higher chemical shift(2 times)

- Spectroscopy
  - Spectra better resolved
  - Spectral editing (GABA, Glx)
- Faster Spectroscopic Imaging
- Peaks can have different shapes

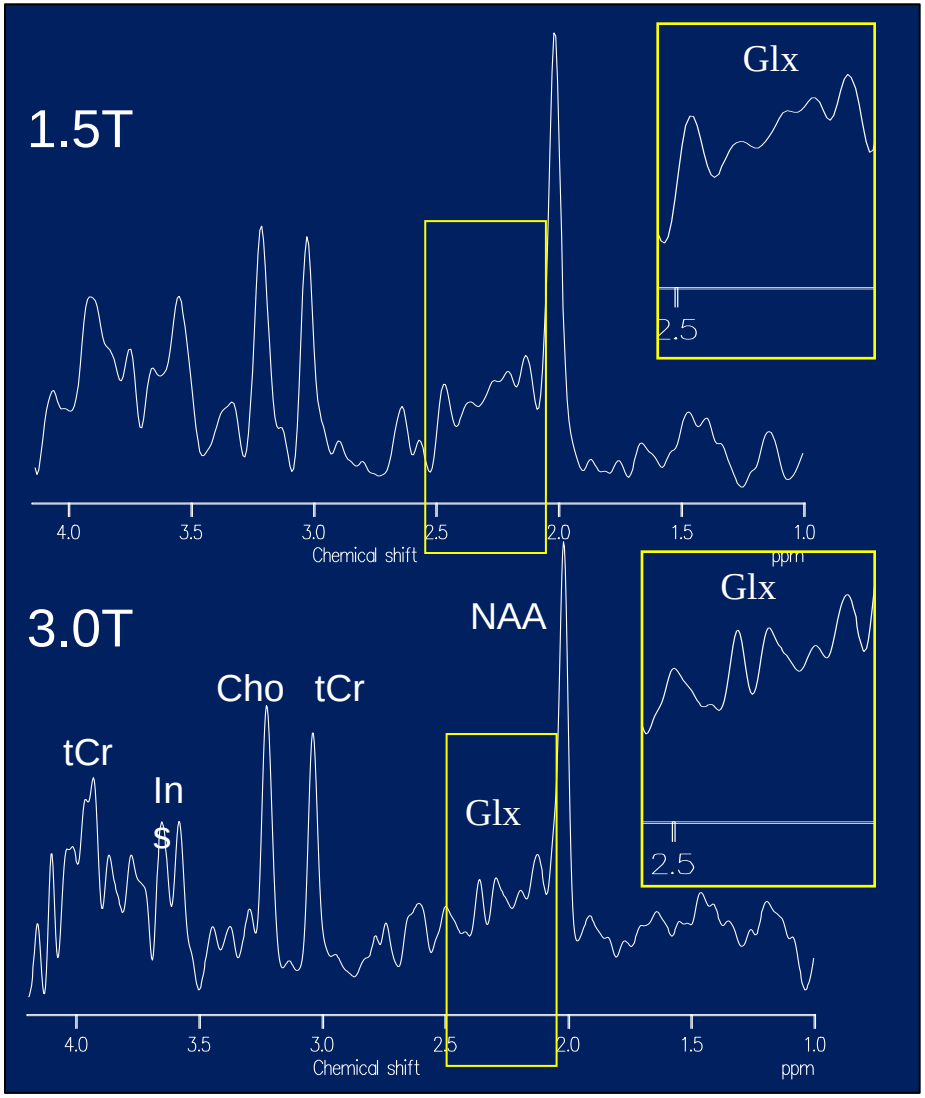

Courtesy: Dept. of Radiology, University of Bonn, Germany

PHILIPS

3T pro

ΔT2* ↑ (Stronger BOLD effect)

fMRI in 10 healthy volunteers

baseline:

- verbal fluency task

activated:

- simple motor task
- lexical decision task
- semantic decision task

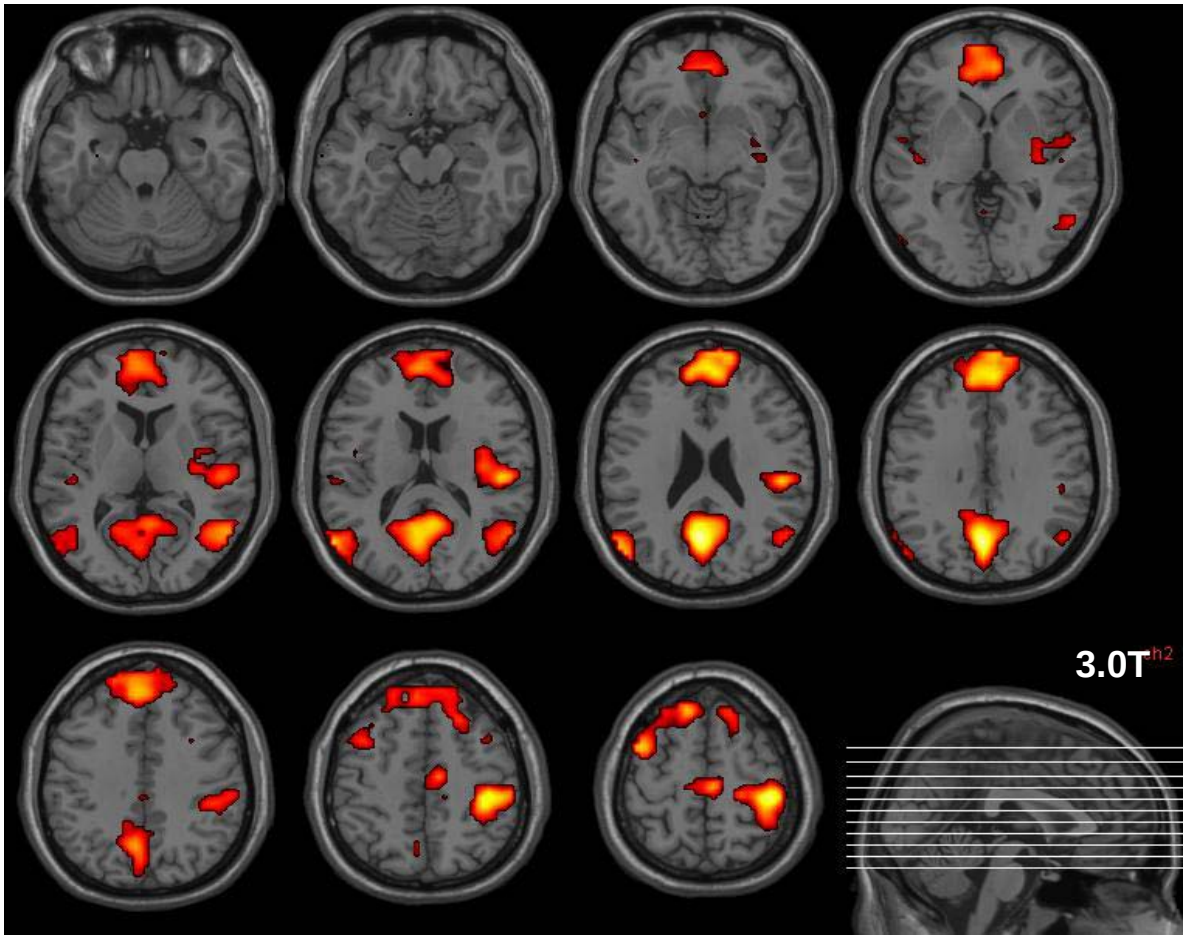

Courtesy: Dept. of Radiology, University of Bonn, Germany

BOLD = Blood oxygenation level dependent contrast

T1 ↑ (storage of M_z)

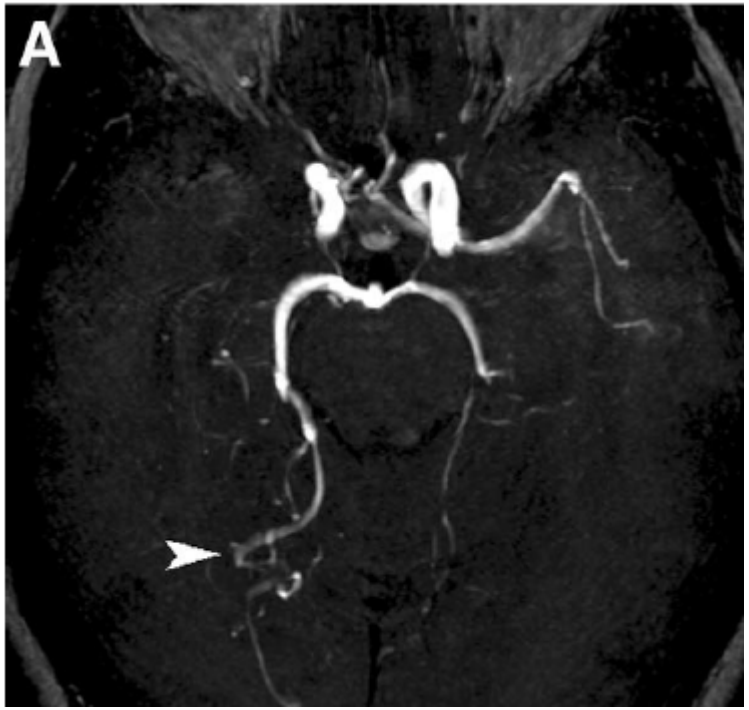

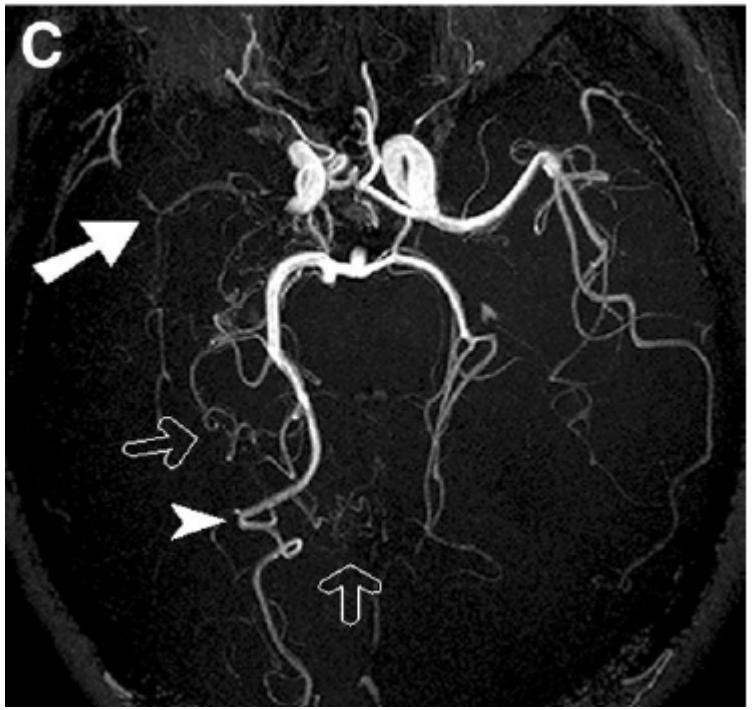

1.5T

3T

Patient with moyamoya disease

Willinek WA et al: Radiology 2003; 229:913–920

PHILIPS

Tagging @ 3T



Phase 1

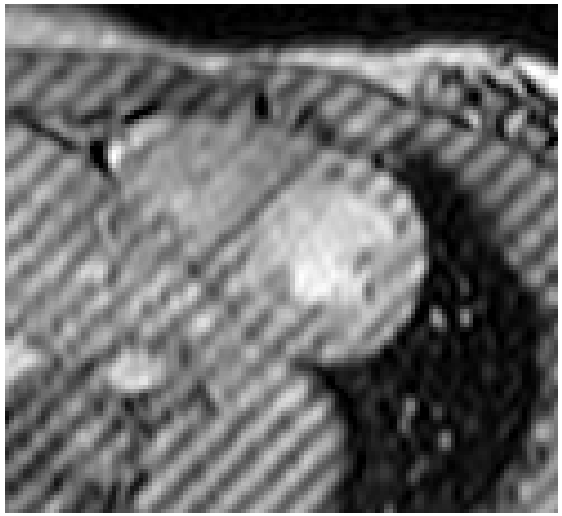

Phase 16

1.5T

CSPAMM

- 51 heart-phases
  13 ms each
- Line tag, 8 mm distance
- Spatial resolution = 2.5 mm
- EPI readout, TE = 6.5 ms

Technische Entwicklungen

B_1- inhomogeneities

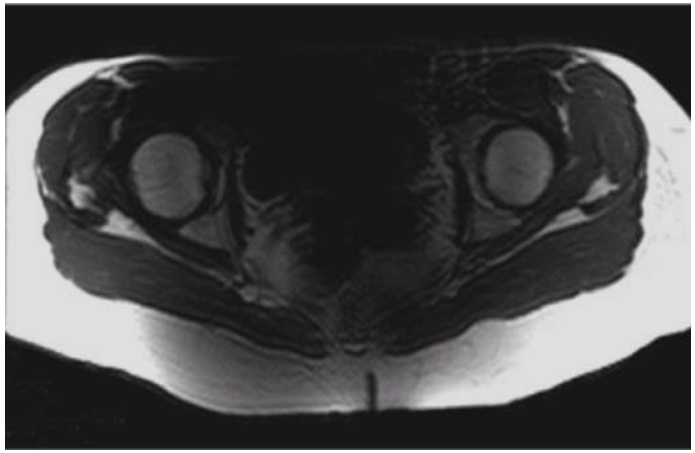

3T: Wavelengh becomes shorter

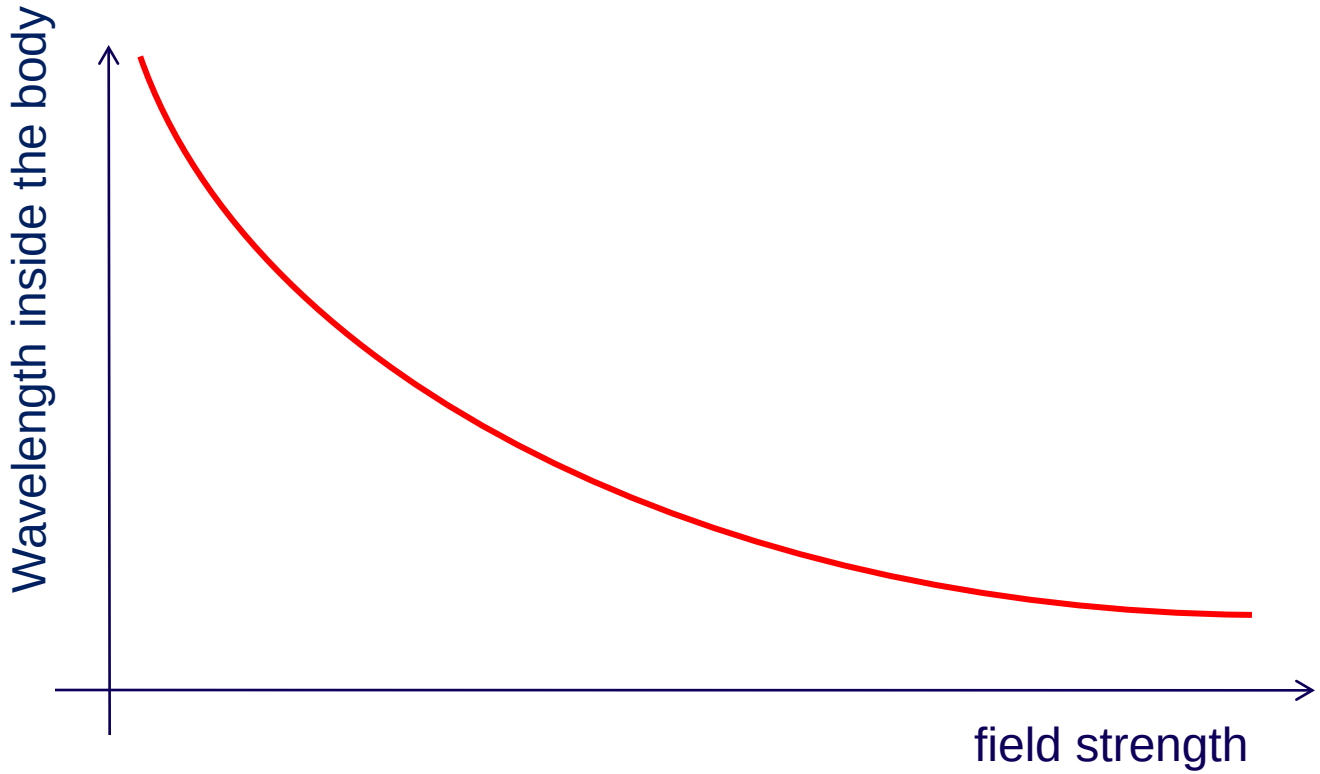

For homogeneous rf- excitation: object must be smaller than wavelength

Standing waves @ 3T

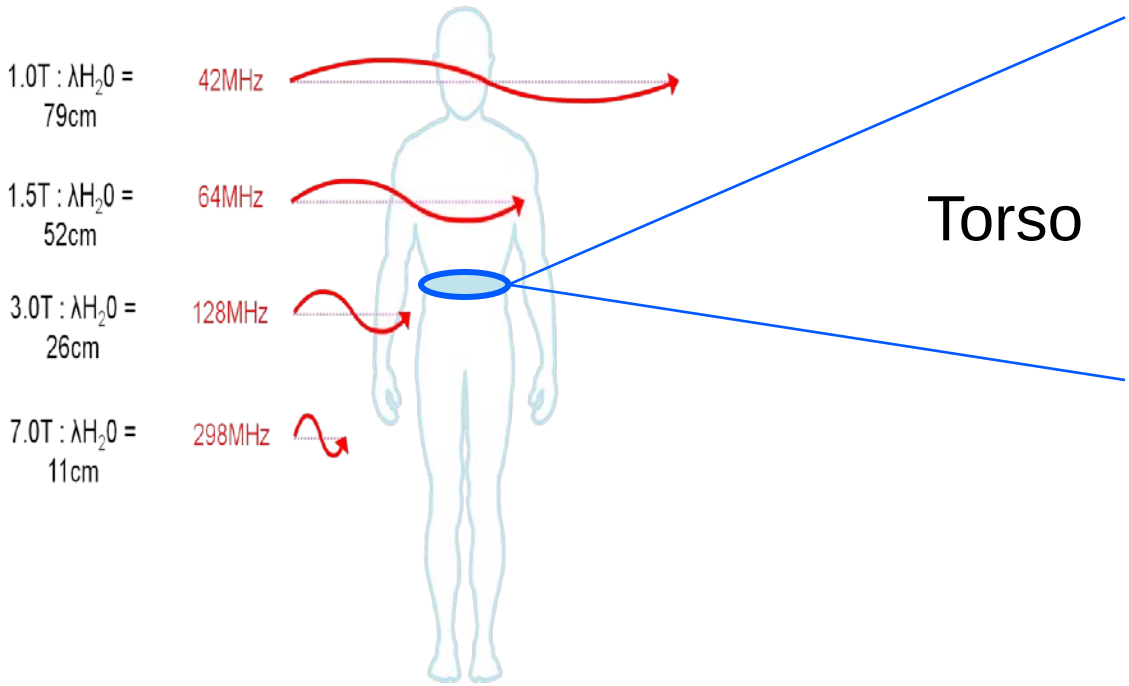

Torso

dielectric shading

Reality (3.0T)

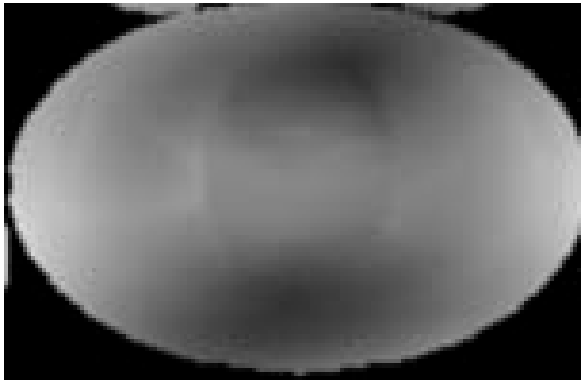

Simulation (3.0T)

$\lambda = (c/f)/\sqrt{\varepsilon}$, $\varepsilon_{H2O} = 81$

ε - dielectric constant

Spine, cardiac, brain …

Dielectric shading (3T)

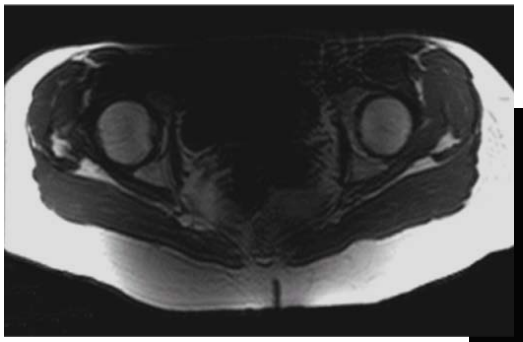

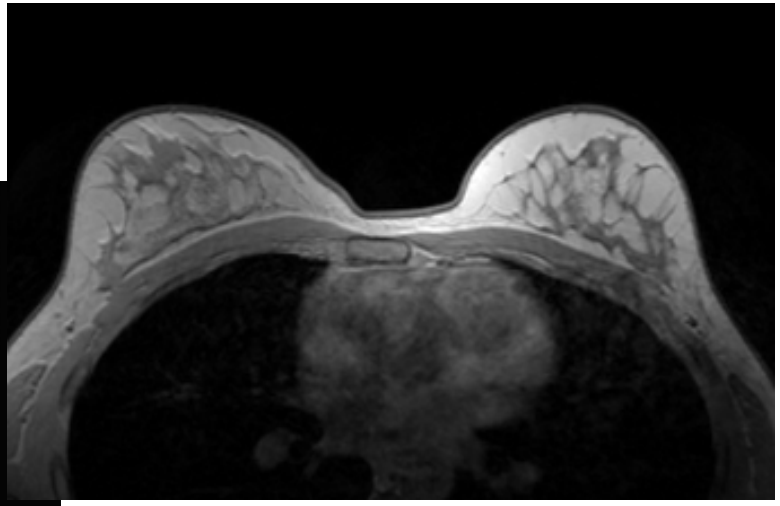

Parallel RF transmission

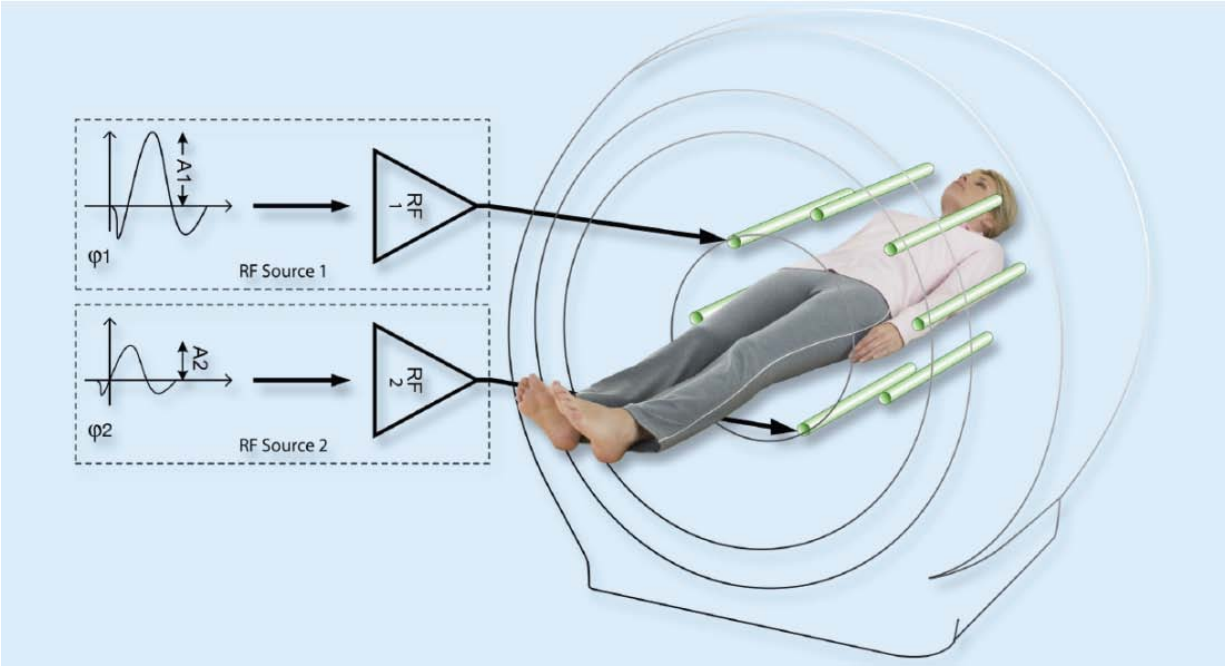

Each source has 4 degrees of freedom: waveform, frequency, amplitude and phase

The RF Shimming (B1 calibration) Procedure

Survey

B1 calibration (1 slice)

B1 Map

B1 ShimTool

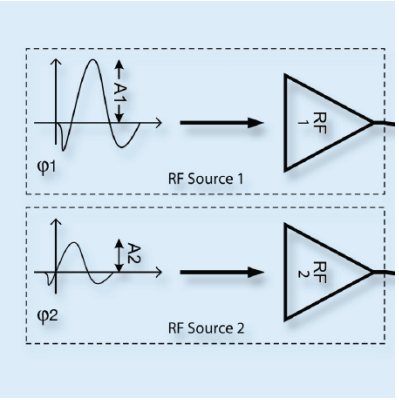

Scanning with MultiTransmit

1. pLA
2. ……

B1 map: flip angle scaled in % of the nominal value

PHILIPS

3T solution

Dual TR Method

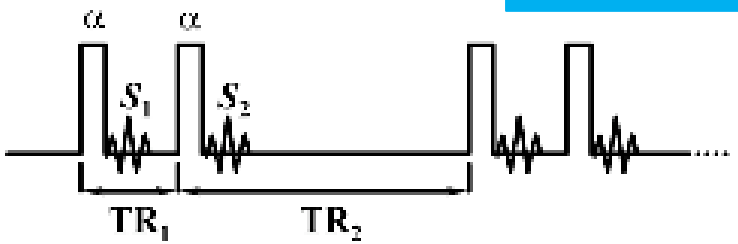

$$S_2/S_1 = r = \frac{1 - E_1 + (1 - E_2)\, E_1 \cos\alpha}{1 - E_2 + (1 - E_1)\, E_2 \cos\alpha}$$

$$E_{1,2} = \exp(-TR_{1,2} / T_1)$$

if $TR_1 < TR_2 < T_1$ ⇒ $r \approx \dfrac{1 + n\cos\alpha}{n + \cos\alpha}$

$$\boxed{\alpha \approx \arccos \frac{rn - 1}{n - r}}$$

$$n = TR_2/TR_1$$

3T solution

Parallel RF transmission @ 3T

Uniformity – breast

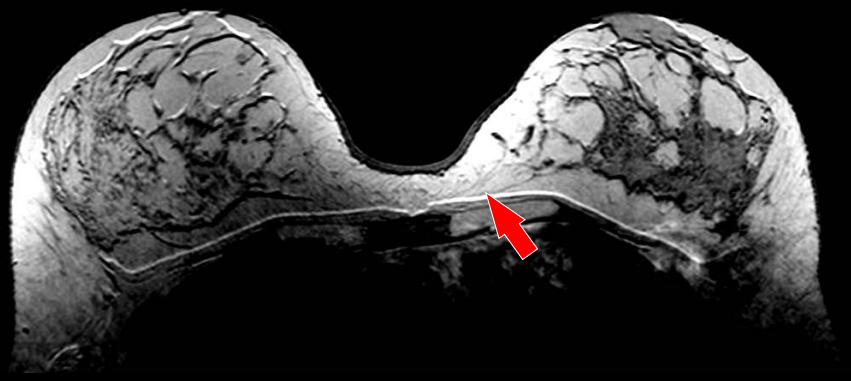

Conventional

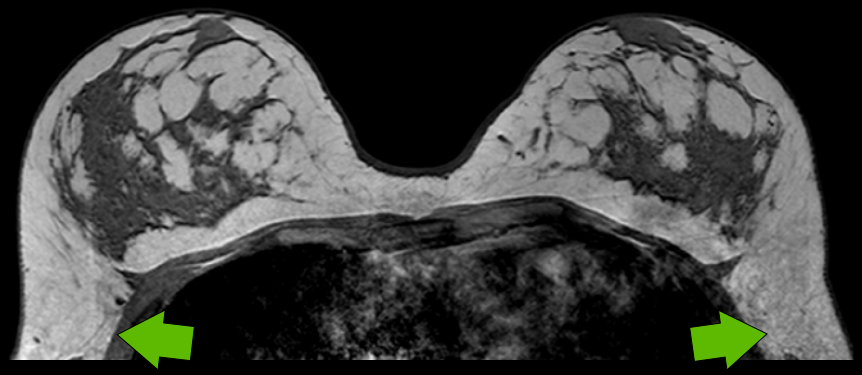

MultiTransmit

Courtesy: Bonn University Hospital

3T solution

Parallel RF transmission @ 3T

Uniformity – spine

Conventional

MultiTransmit

T2W TSE

3T solution

Parallel RF transmission @ 3T

Uniformity – heart

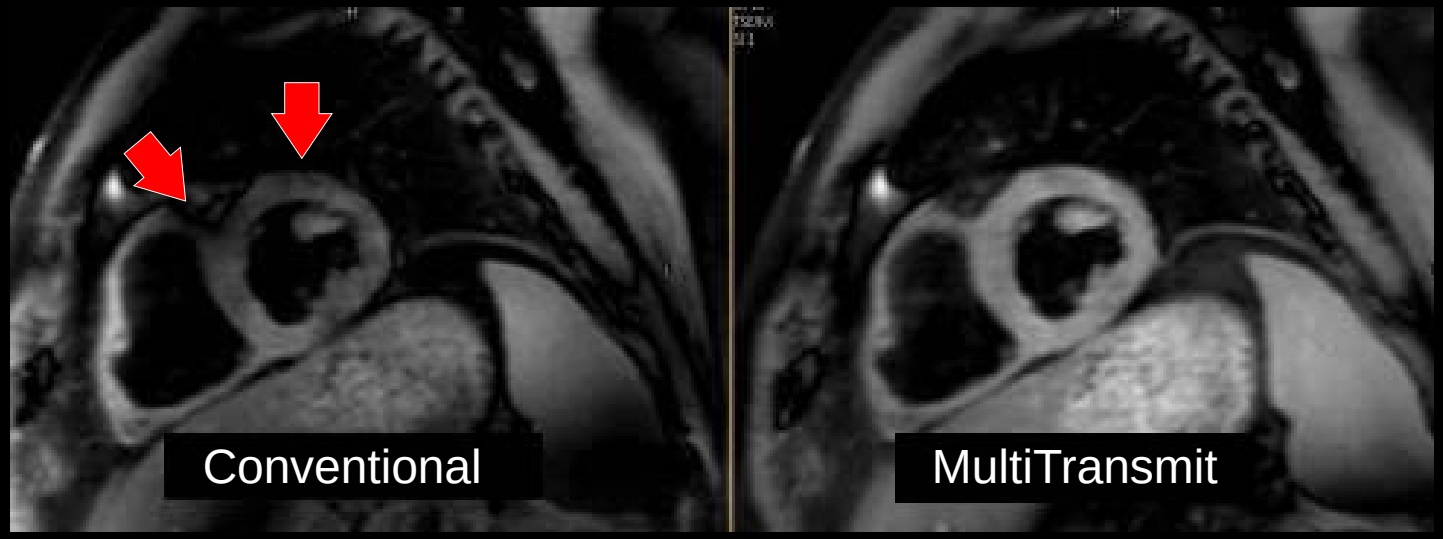

PD Black-blood IR-TSE + SPAIR

3T solution

Parallel RF transmission @ 3T

Uniformity – Liver – Challenging ascitis patients

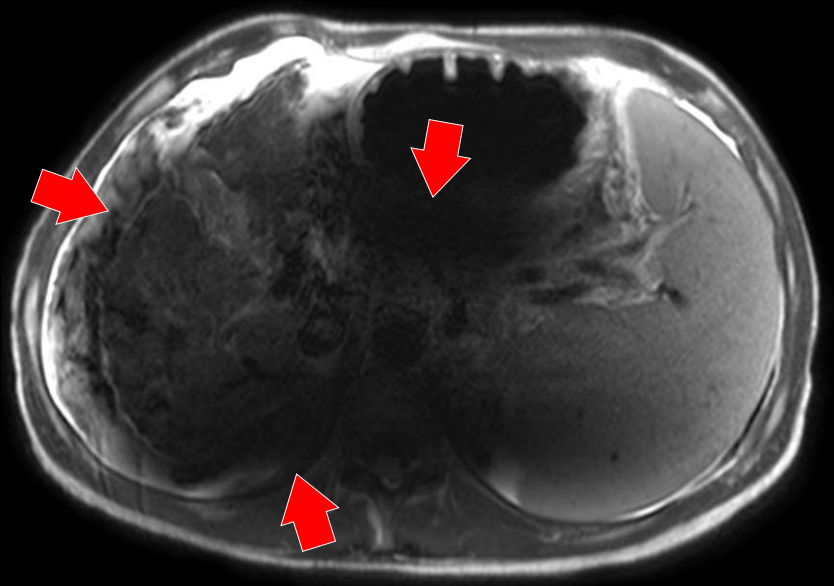

Conventional
(*well known shading from fluids*)

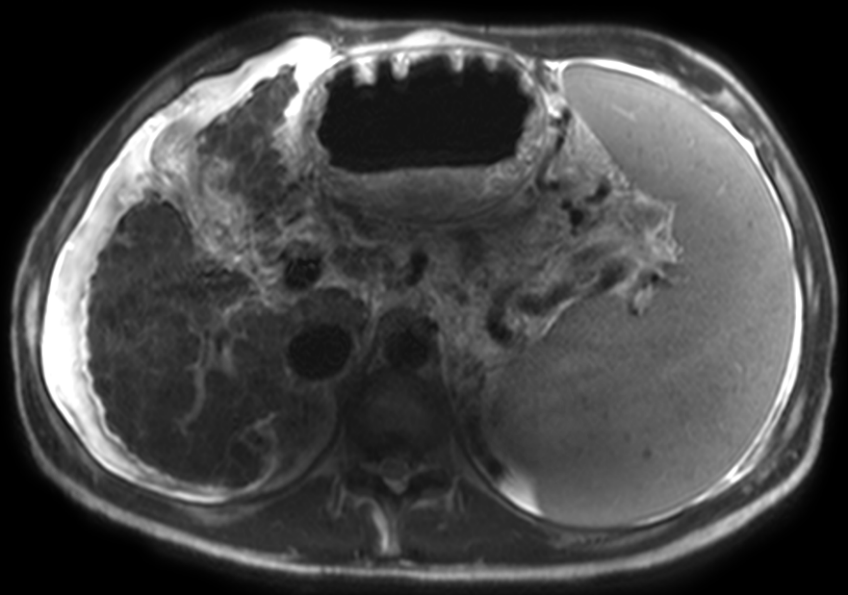

MultiTransmit

T2W TSE Ssh, 1.2 x 1.4 x 7mm, 25 slices, 14 sec

Courtesy: Bonn University Hospital

PHILIPS

Courtesy: Bonn University Hospital

Polycystic liver disease

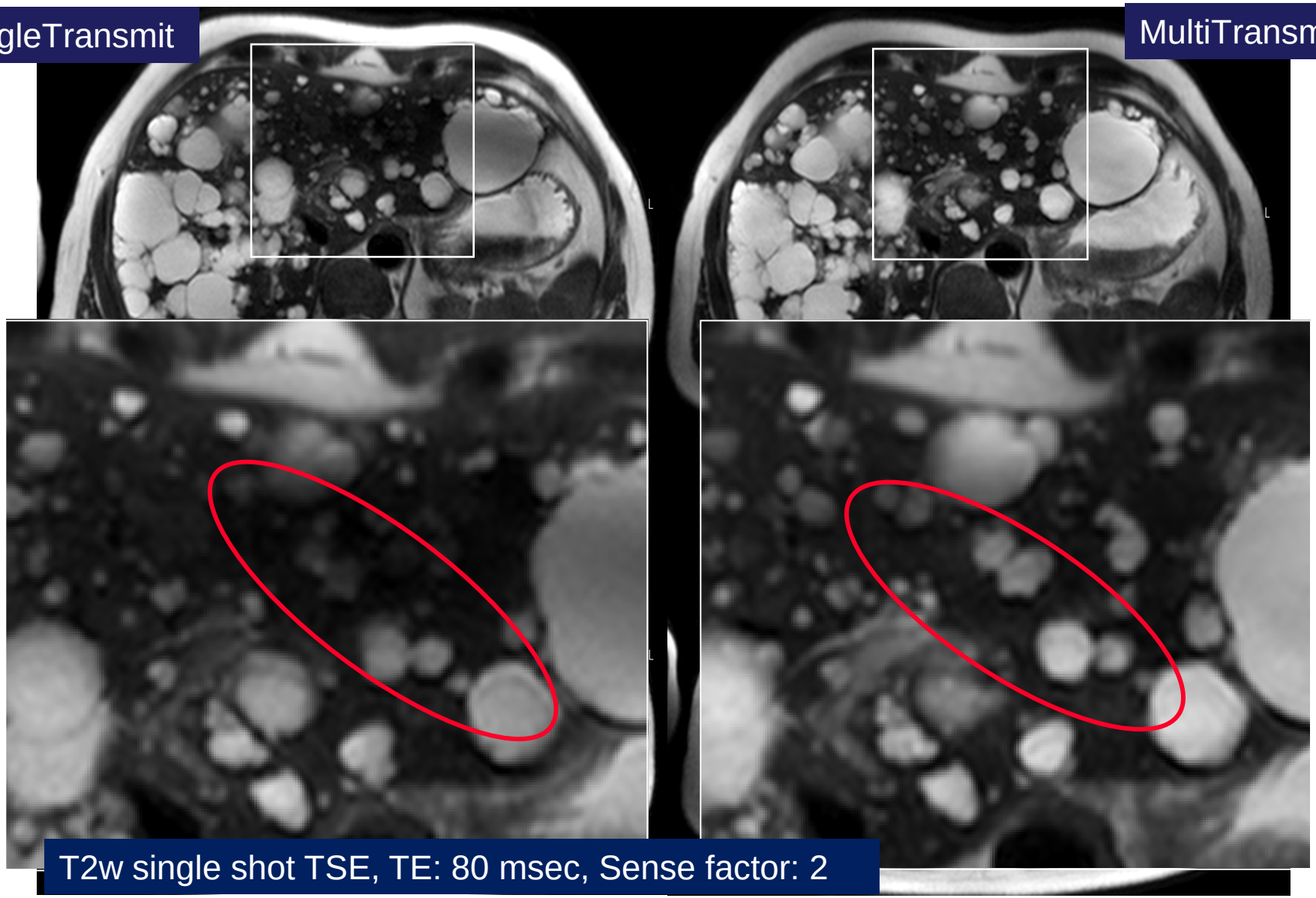

T2w single shot TSE, TE: 80 msec, Sense factor: 2

SAR* limitations ($SAR_{3T} = 4\ SAR_{1.5T}$)

Can lead to:

- longer TR times
- poorer coverage
- longer RF pulses

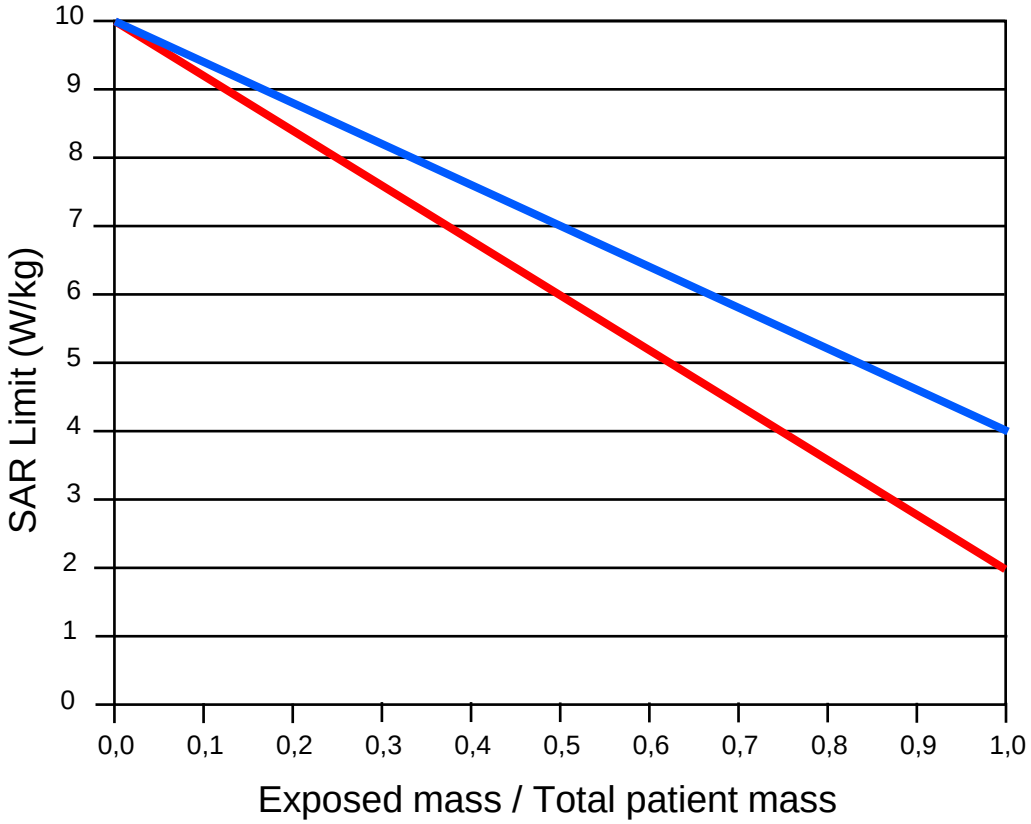

*Specific Absorbtion Rate

SAR limitations

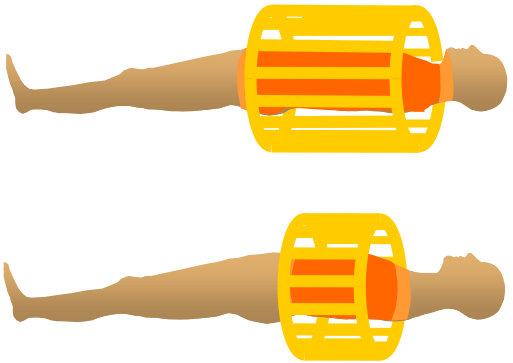

Local SAR

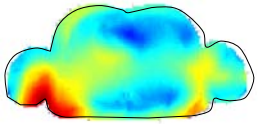

SingleTransmit

MultiTransmit

Technical developments:

- optimized body coil design (e. g. shorter coil)
- Multi-transmit RF-system (reduces energy deposition hotspots)
- Multi-channel receive (parallel imaging)
- Flip angle sweep (TSE)

TSE - Flip angle sweep (FAS)

RF deposition high (large # of 180° pulses)

Flip Angle Sweep (FAS)

➔ variable flip angle of the refocussing pulses along the echotrain

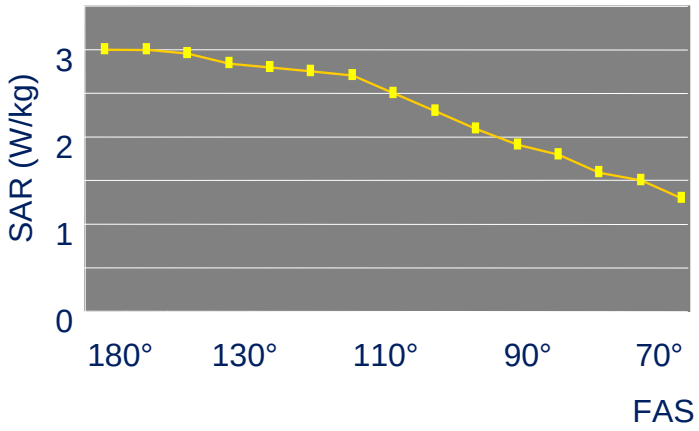

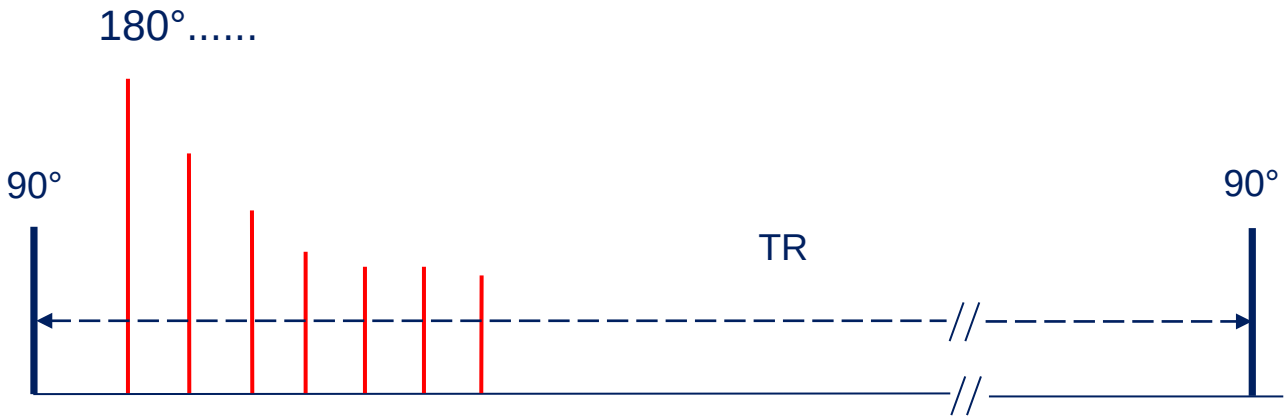

Courtesy: Jürgen Gieseke, Bonn

TSE - Flip angle sweep (FAS)

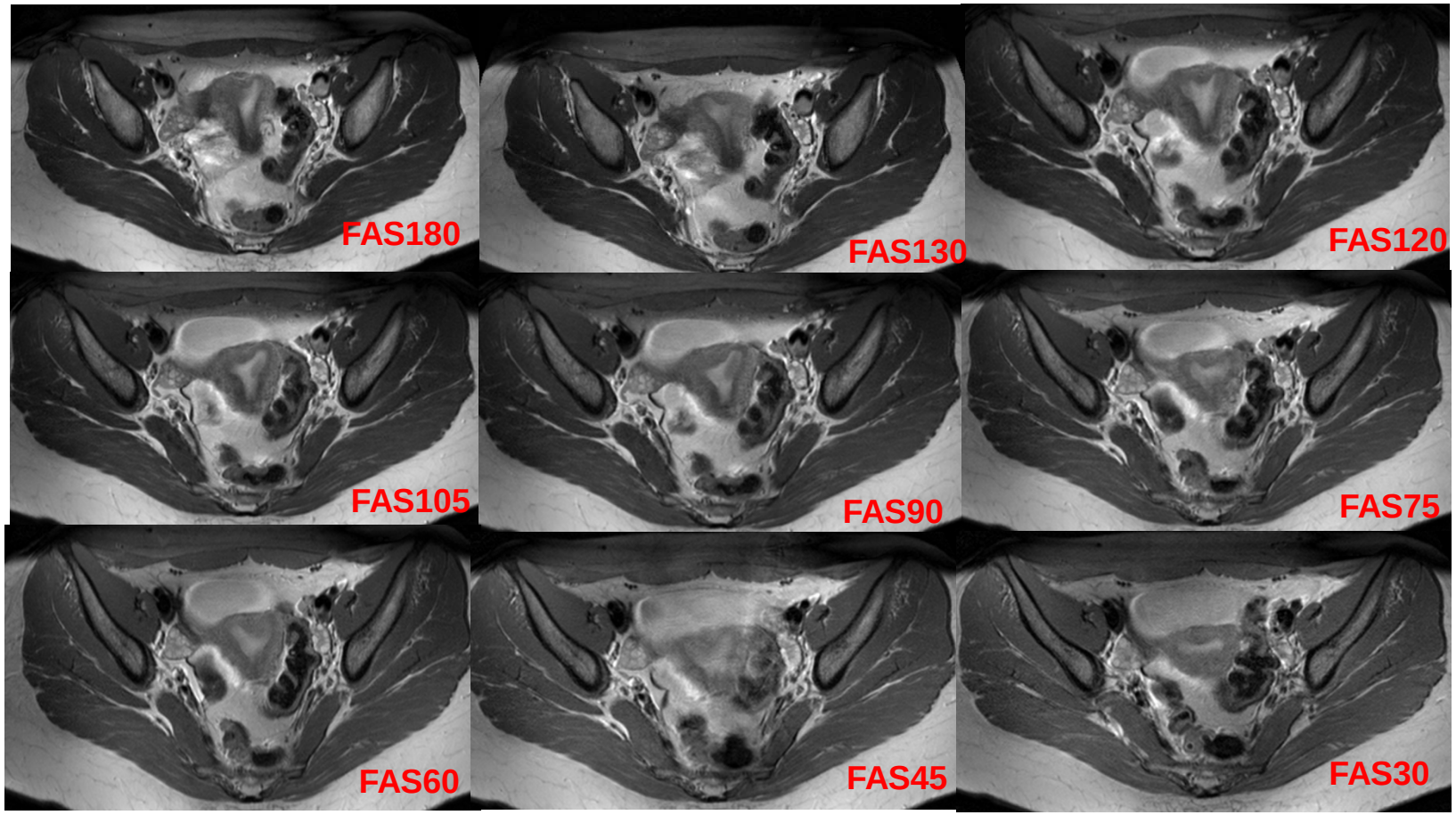

T2 TSE, SENSE 2

Jürgen Gieseke, RöKo 2004

Parameter changes 3T vs. 1.5T

pro	contra
SNR ↑ (factor 2)	SAR $\propto \omega^2$ (i.e. factor 4 !) ↑ ↑ ✓
Chemical shift ↑ (spectroscopy, fat suppr.)	Chemical shift artefact ↑
T1 ↑ (storage of M_z; e. g. inflow angio)	T1 ↑ (TR ↑)
Δ T2* ↑ (BOLD)	T2* ↓
	Suszeptibility effects ↑
	B_1- inhomogeneities ↑ ✓
	MHD artefakt ↑

SAR = specific absorbtion rate

Parameter changes 3T vs. 1.5T

SNR ↑ (factor ≈ 2)

- Higher spatial resolution
- Higher acceleration factors for parallel imaging
- Larger coverage in the same scan time

SAR = specific absorbtion rate

PHILIPS

Coil improvements

“digital“ coils, i.e. ADC within the coils

higher SNR

ADC

PHILIPS

Klinische Beispiele

Utra-high-resolution TOF-MRA

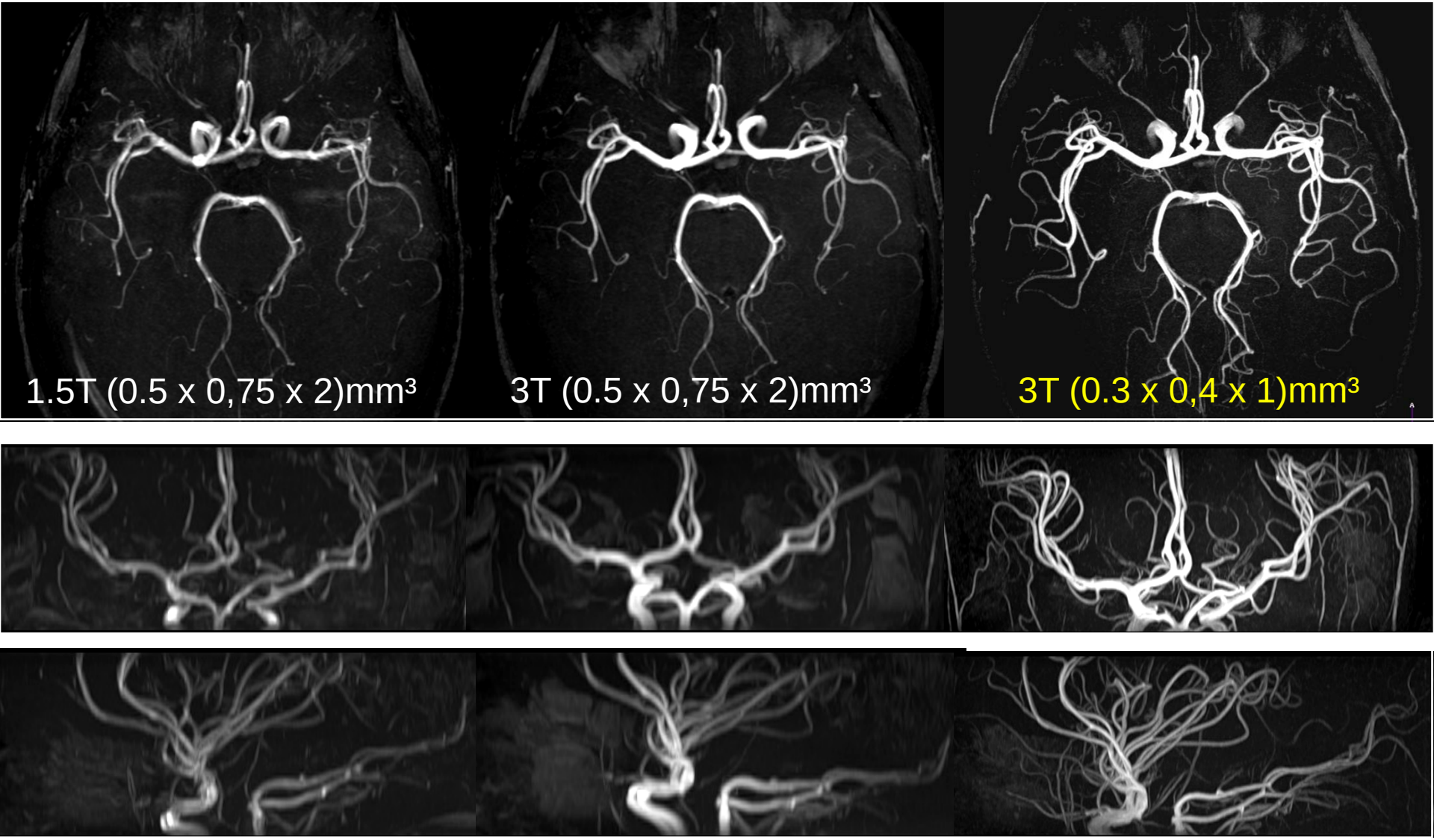

Willinek WA et al: Radiology 2003 (229) 913

Utra-high-resolution TOF-MRA

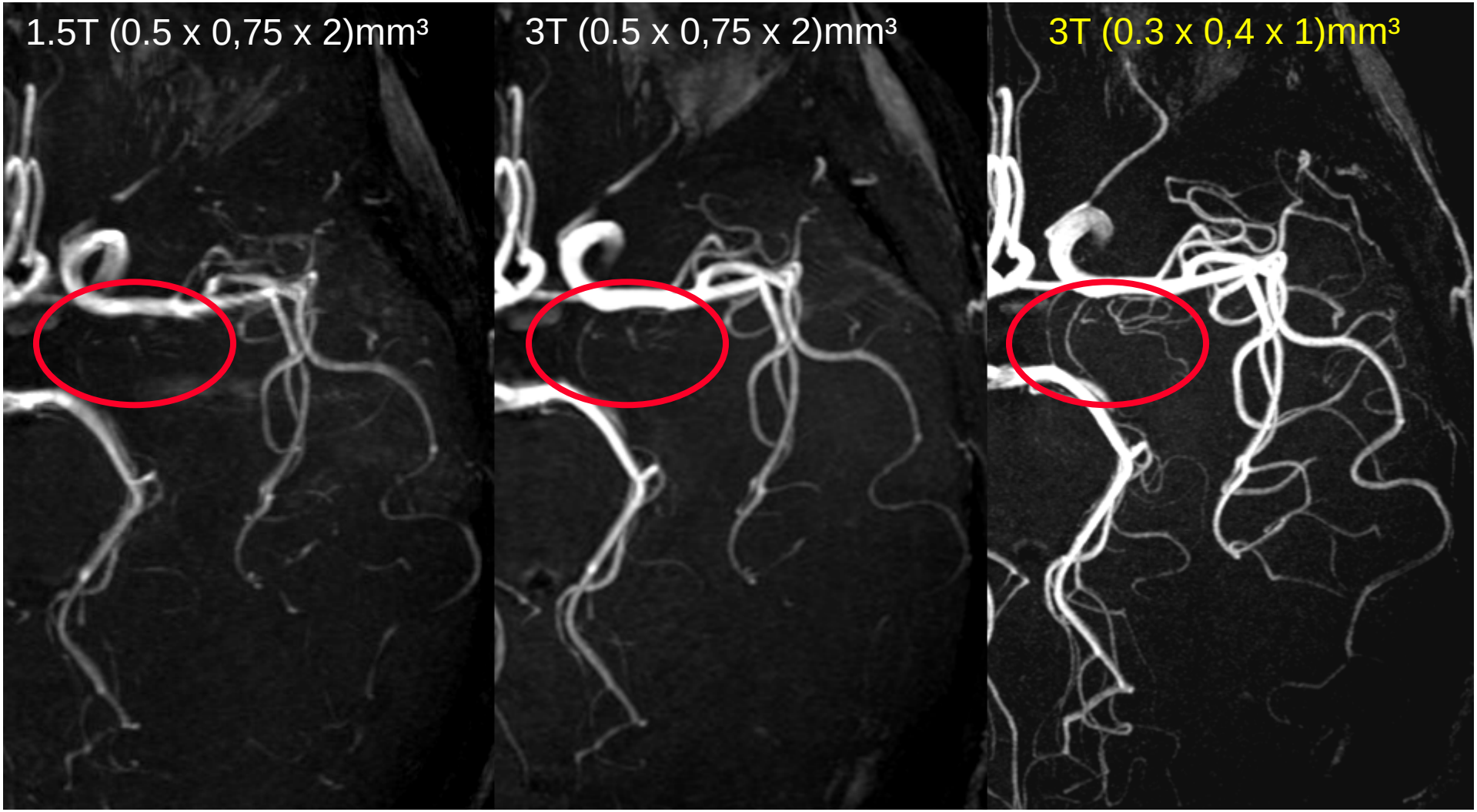

Willinek WA et al: Radiology 2003 (229) 913

Utra-high-resolution TOF-MRA

1.5T (0.5 x 0,75 x 2)mm³ 3T (0.5 x 0,75 x 2)mm³ 3T (0.3 x 0,4 x 1)mm³

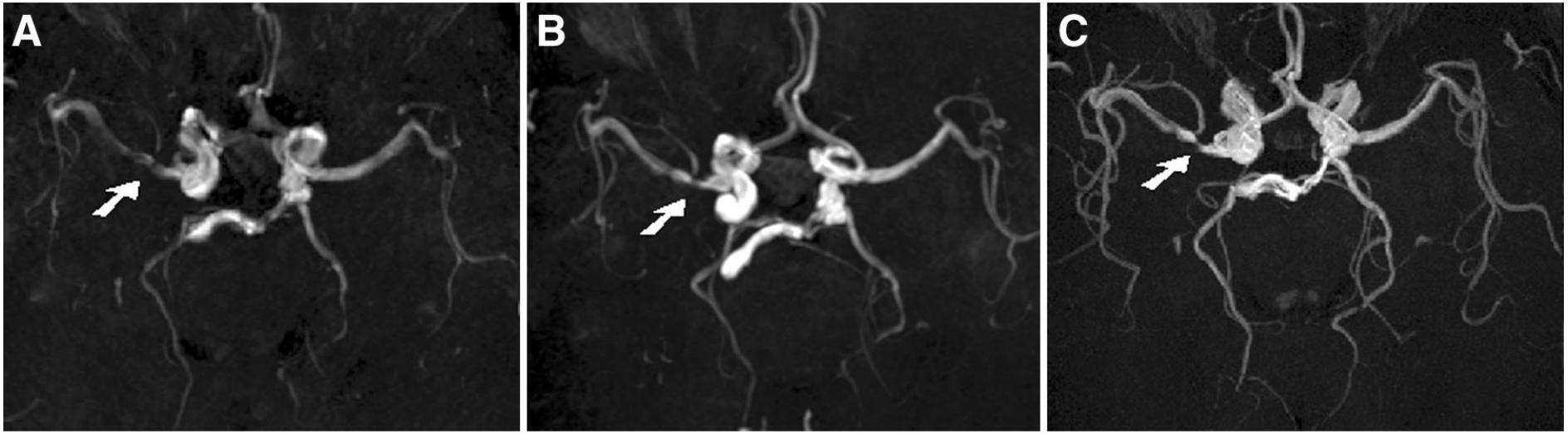

In *A, right MCA stenosis (arrow) is not displayed as clearly as it is in B and C.*

MCA: middle cerebral artery

Willinek WA et al: Radiology 2003 (229) 913

Detection of inflammatory brain lesions in patients with multiple sclerosis

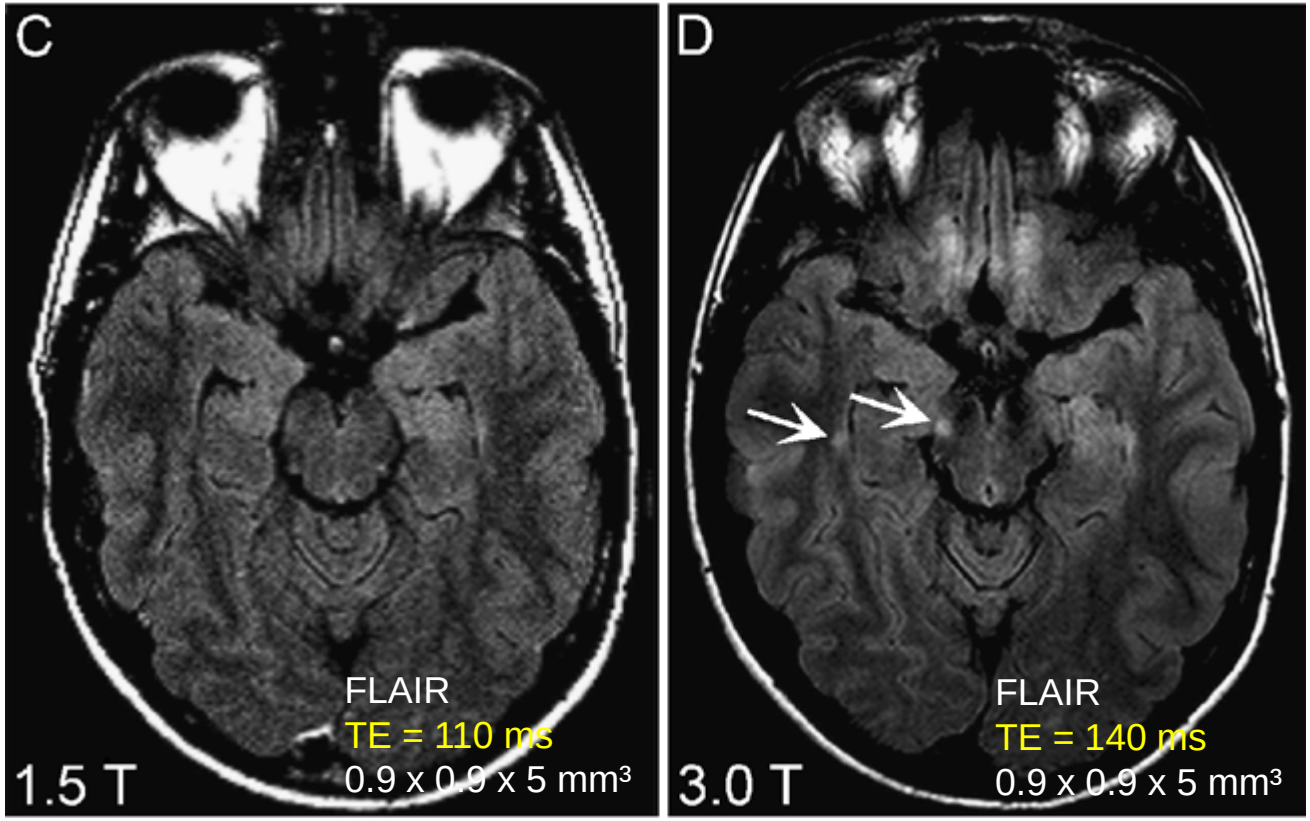

3.0 T provides a significantly higher detection rate of inflammatory brain lesions

Wattjes M et al: Europ Radiol 2006 (16) 2067

Brain Tumors: Full- and Half-Dose Contrast-enhanced MR Imaging at 3.0 T vs.1.5 T

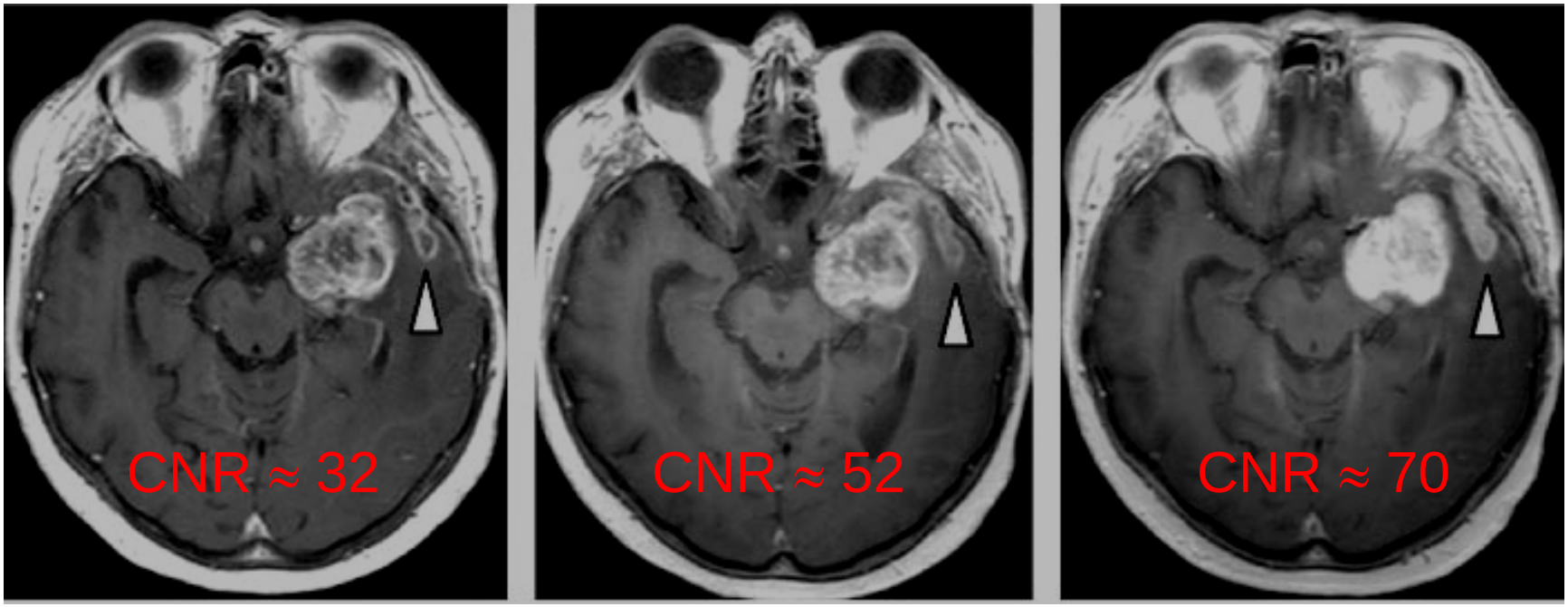

1.5T (0.1 mmol/kg CA*) | 3T (0.05 mmol/kg CA) | 3T (0.1 mmol/kg CA)

*Magnevist

Krautmacher C et al: Radiology 2005 (237) 1014

Quantitative and qualitative comparison of 1.5T and 3.0T MRI in patients with chronic liver diseases

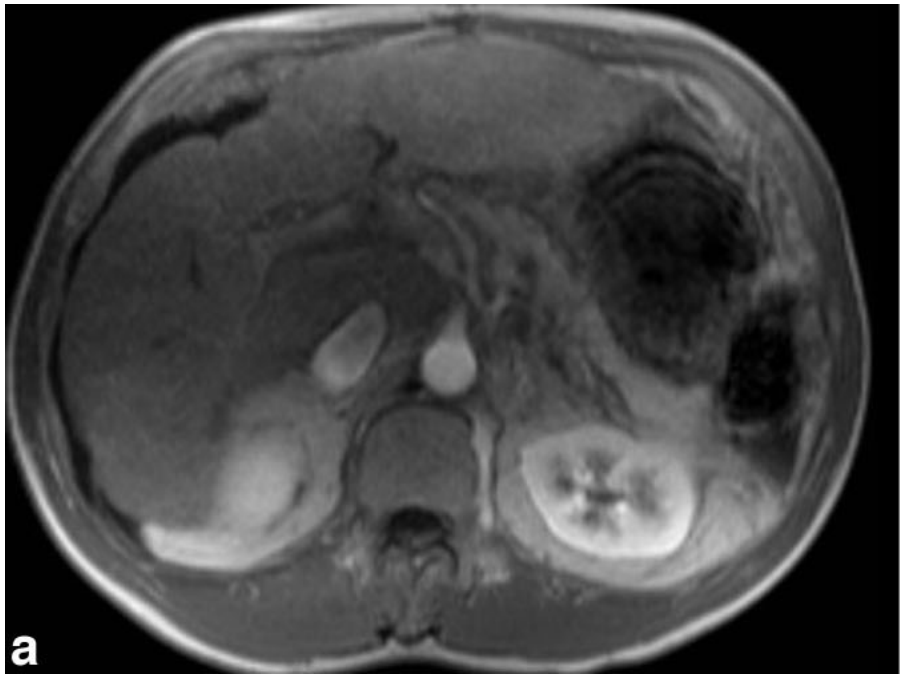

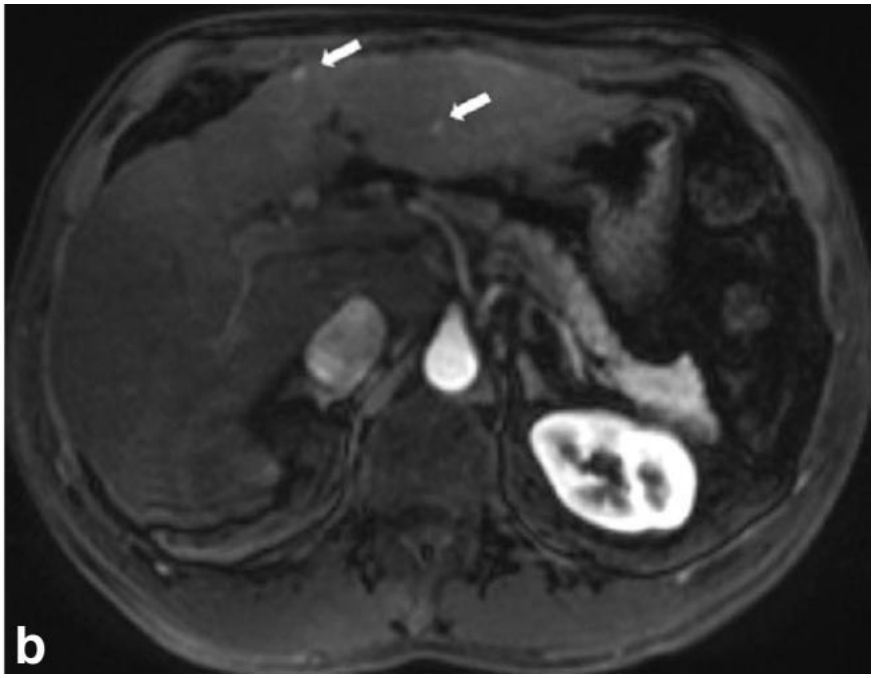

1.5T: 3D-T1W-GRE (post CA)
1.8 x 1.4 x 8 mm³

3T: 3D-T1W-GRE (post CA)
1.9 x.1.8 x 3 mm³

Ramalho M et al: J Magn Reson Ima 2009; 29: 869

Kuhl CK. et al: Radiology 2008 Vol. 247; 16

MR imaging of the female pelvis @ 3T

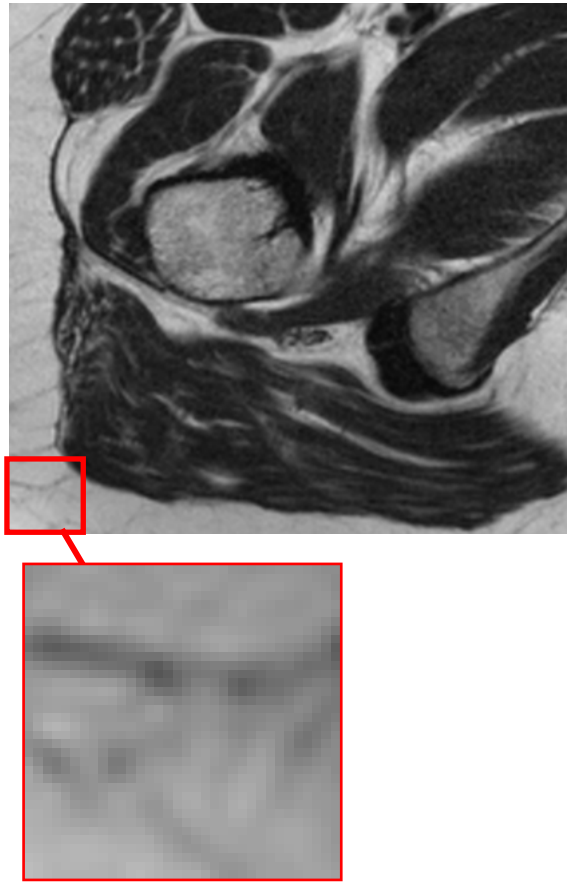

1.5T
4:19 min
0.85 x 0.85 x 4 mm³

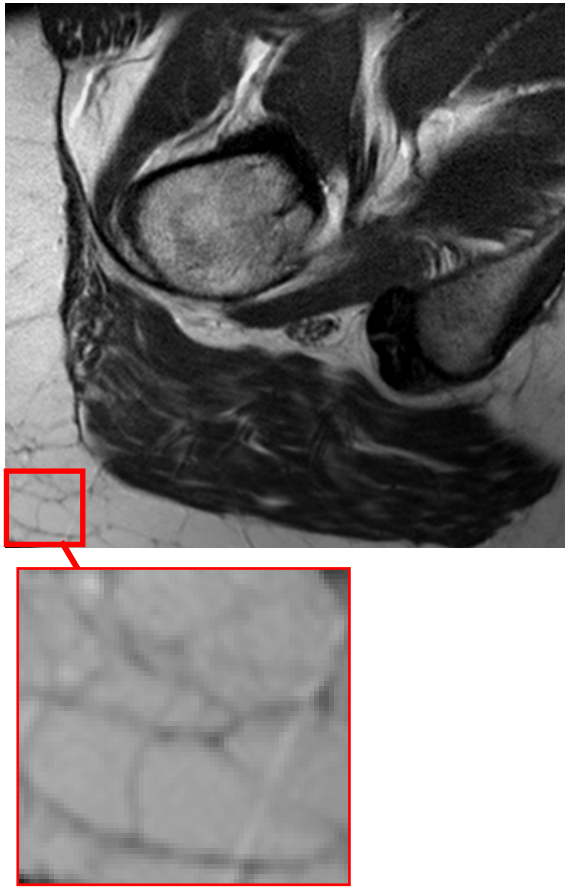

3.0T
6:18 min
0.45 x 0.45 x 4 mm³
parallel imaging (factor 3)

PHILIPS

MR imaging of the female pelvis @ 3T

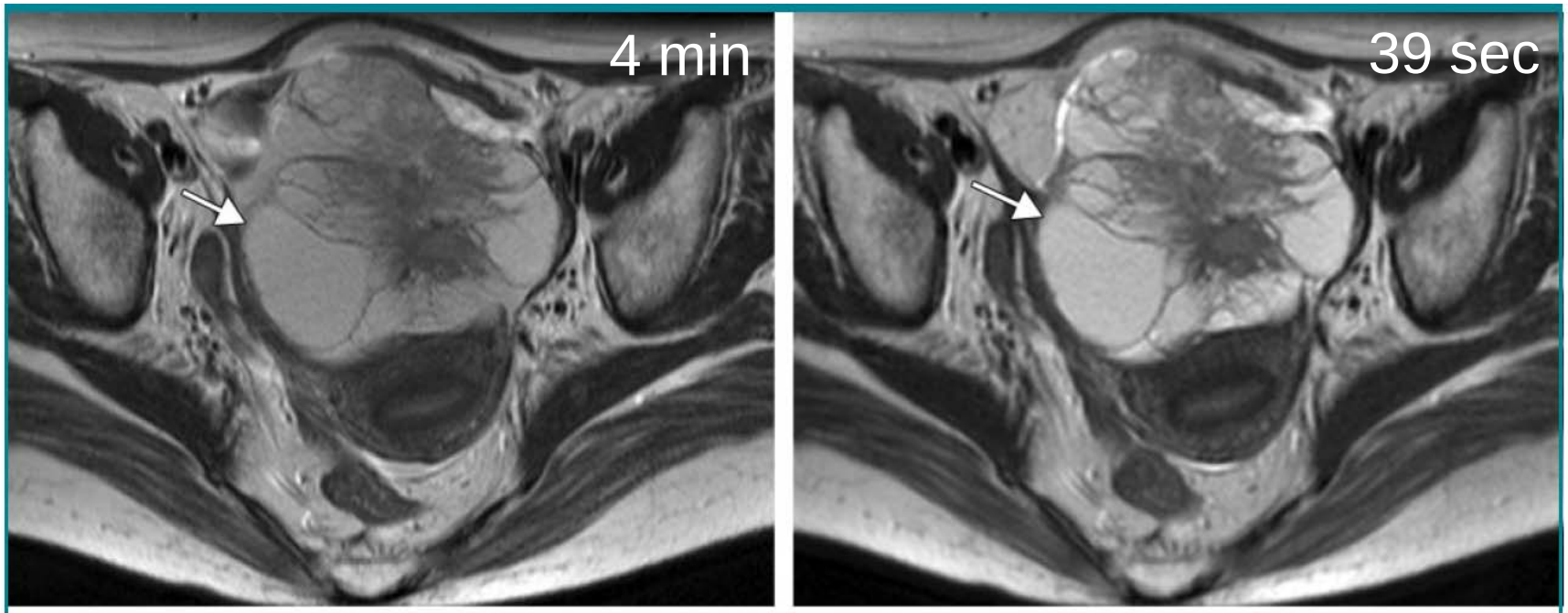

a. b.

Figure 2: Transverse T2-weighted MR images in 53-year-old patient with ovarian cancer obtained with **(a)** standard sequence (2705/80; imaging time, 4 minutes 3 seconds) and **(b)** fast sequence (4933/100; imaging time, 39 seconds). Image quality of both sequences is comparable. In **b**, signal intensity of cystic tumor components (arrow) is increased. The remaining tissue contrasts in the two images are comparable.

spatial resolution : 0.7 x 1 x 4 mm^3

Morakkabati-Spitz N. et al: Radiology 2006 Vol. 241; 538

4D-Angio of cerebral arteriovenous malformation

Brain AVM
1.2 x 1.4 x 1.1 mm

140 slices
0.66 s / volume

SENSE x 8
keyhole x6
HS x1.25

3.0T

Subsecond whole brain 4D MRA

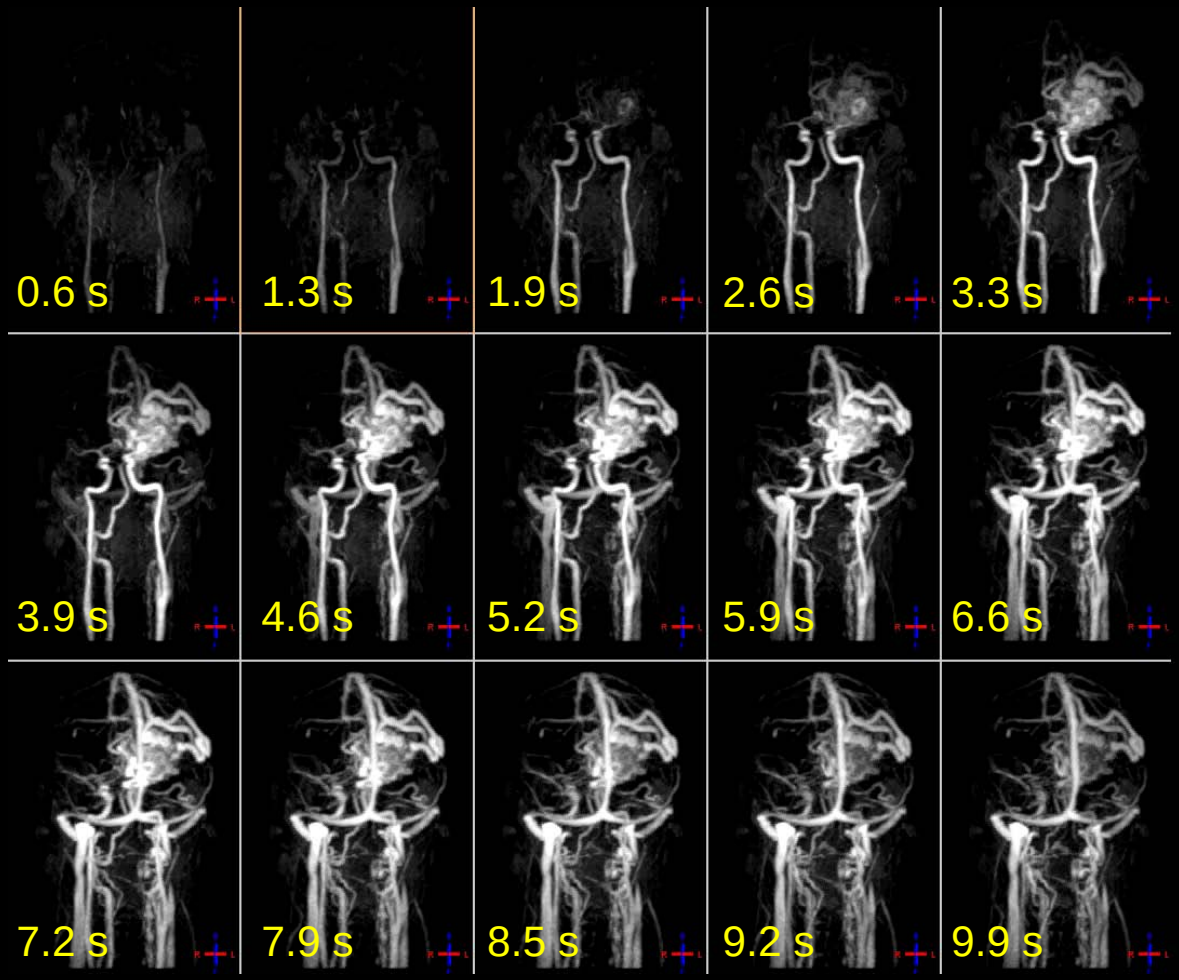

Courtesy: Bonn University Hospital, Germany

4D-Angio: AVM

Excellent agreement with DSA

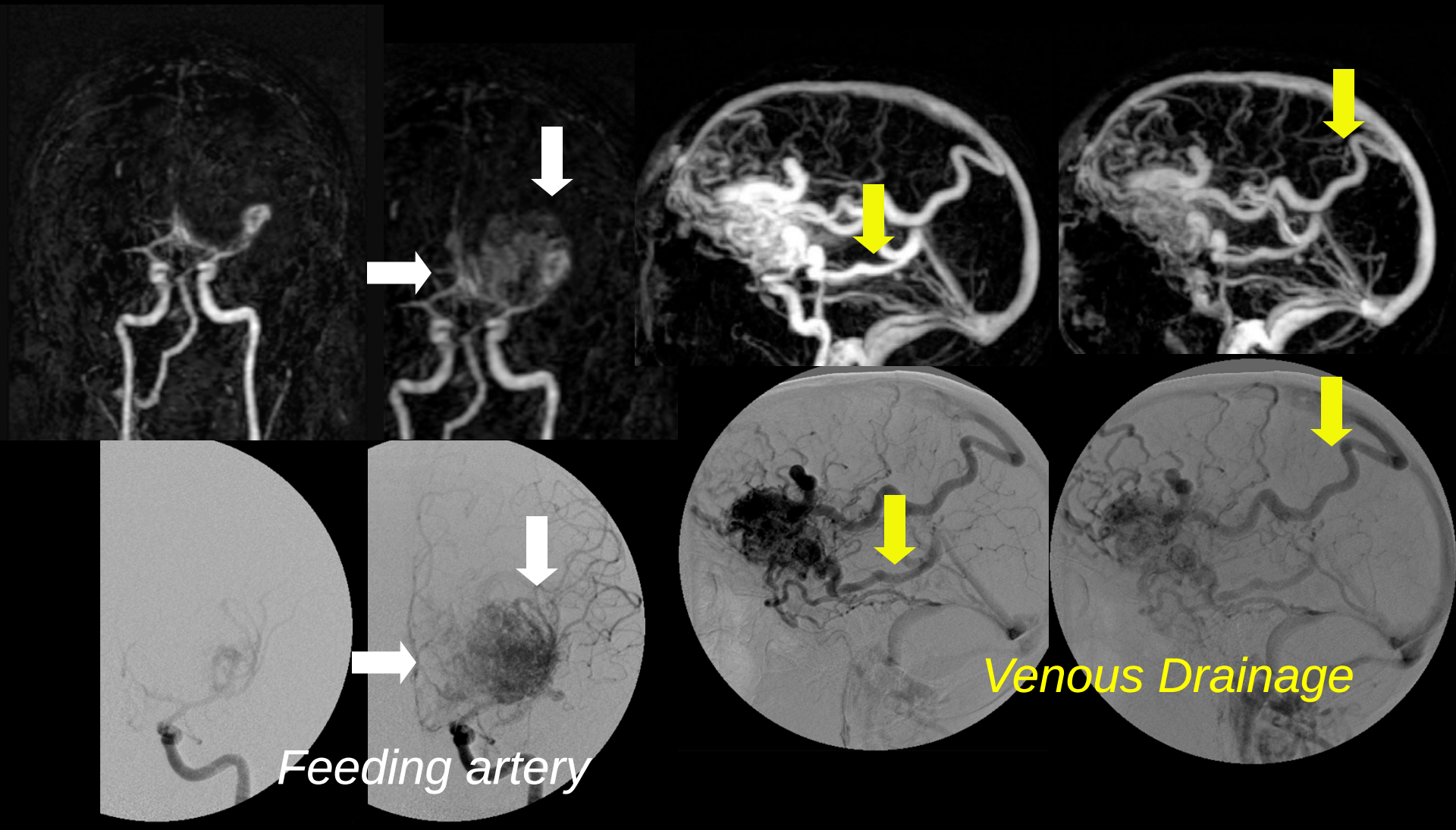

Courtesy: Bonn University Hospital, Germany

4D-Angio of Cerebral Arteriovenous Malformation (AVM)

Conclusion: Subsecond-temporal-resolution 4D contrast-enhanced MR angiography at 3T had 100% agreement with DSA with regard to Spetzler-Martin classification of cerebral AVM.

Hadizadeh DR et al: Radiology 2008; 246: 205

Functional breast MR

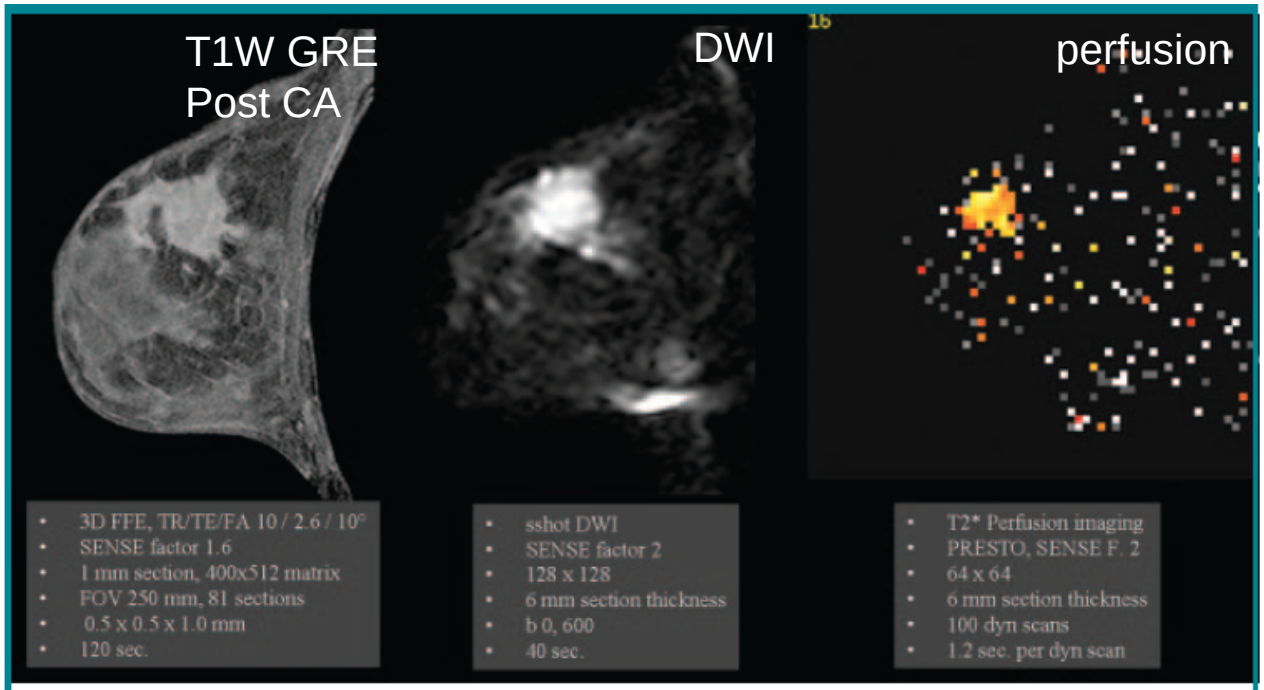

Figure 7: Images in the same patient as in Figure 6. Left: Sagittal high-spatial-resolution actively fat-suppressed postcontrast three-dimensional *(3D)* turbo gradient-echo (10/2.6, 10° flip angle) imaging. *FA* = flip angle, *FFE* = fast field echo, *FOV* = field of view, *TE* = echo time, *TR* = repetition time. Middle: Sagittal diffusion-weighted parallel imaging with a reduction [SENSE] factor of two. *Sshot* = single shot. Right: Sagittal turbo gradient-echo T2* first-pass perfusion imaging (principles of echo shifting with a train of observation *[PRESTO]*, SENSE factor of two) displays the parametric map revealing maximum perfusion-mediated signal intensity loss as surrogate for regional tumor perfusion volume. Note the restricted diffusion at the site of the cancer and the very strong perfusion on the perfusion map.

Kuhl CK. et al: Radiology 2008 Vol. 247; 16

PHILIPS

3T vs. 1.5T

Application:

- Multiple sclerosis +
- Brain tumors +
- Stroke -/+
- Brain function +
- Spine -/+
- Vascular +
- Cardiac -/+
- Abdomen -/+
- Breast -/+
- Pelvis +
- Musculoskeletal -/+

+	better results
-/+	equal or better results (further studies necessary)

See also : Willineck WA et all : Europ J Radiol 65 (2008) 2

Zukünftige Entwicklungen (Beispiel)

BOLD cardiovascular imaging

Blood Oxygenation Level Dependent Contrast cardiovascular imaging (myocardial perfusion)

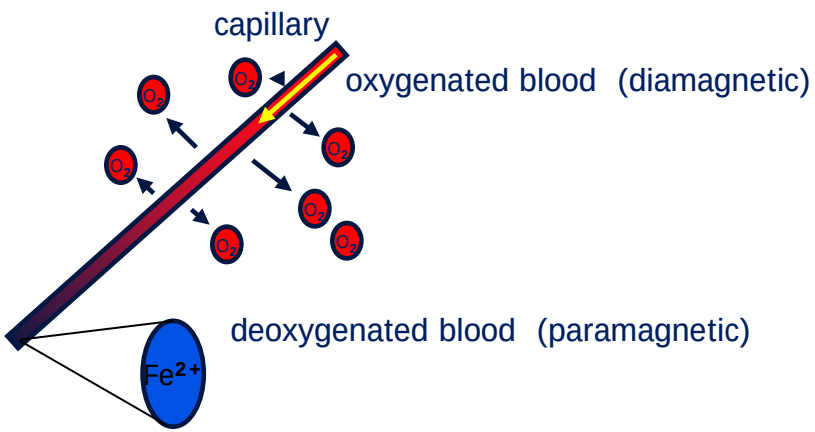

- deoxyHbg can be used as endogenous contrast agent to visualise tissue oxygenation
- MR signal depends on the ratio of oxyHbg/deoxyHbg, field strengh, blood flow, blood volume
- BOLD effect $\propto B_0$

PHILIPS

Study design

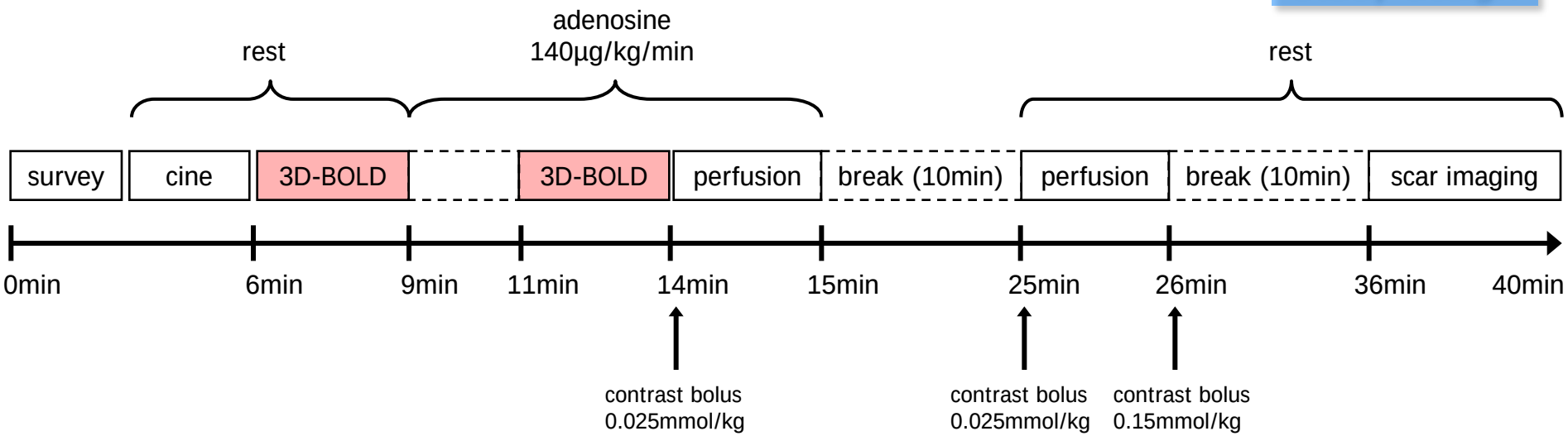

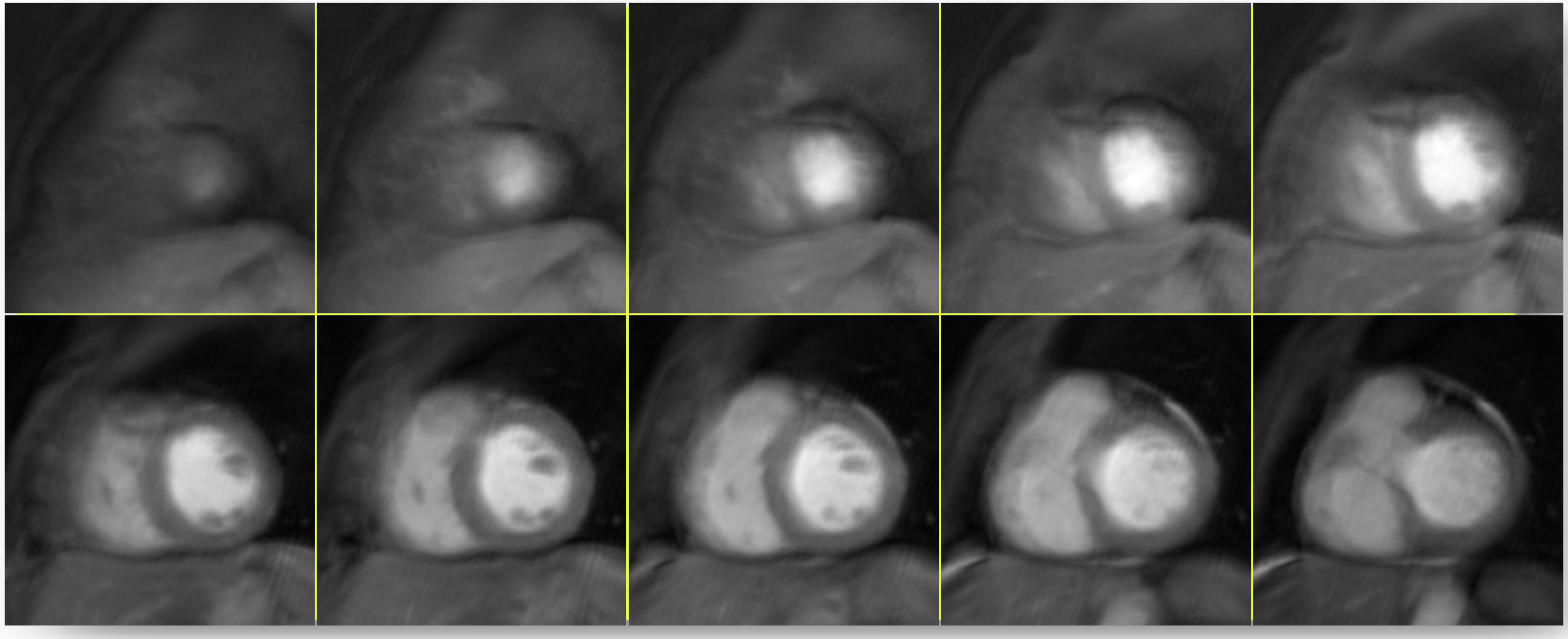

Jahnke C et al: JACC CV Imaging 3 (2010) 375-84

BOLD Imaging: example

BOLD ΔSI

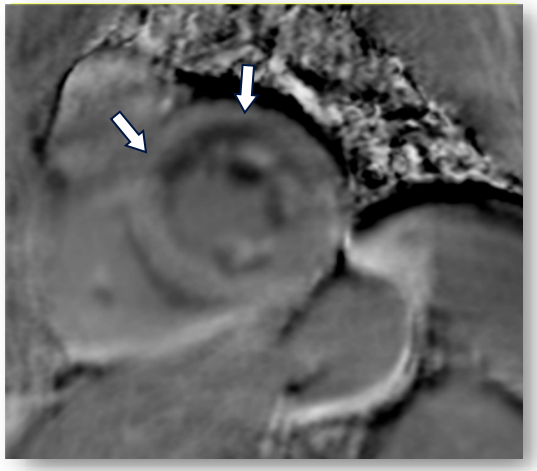

BOLD ΔSI colour map

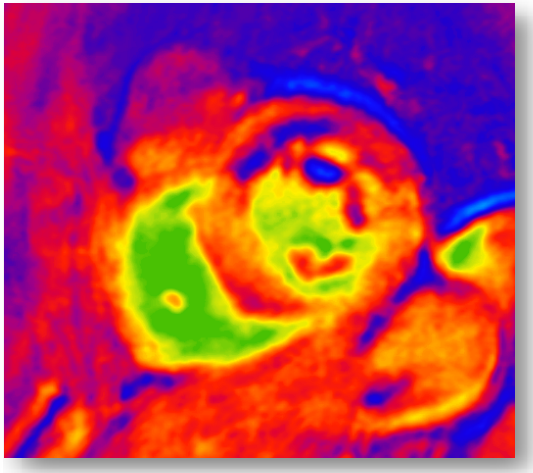

Invasive X-ray angiography

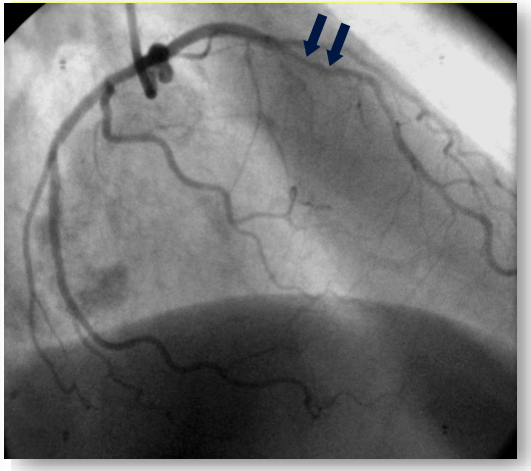

$$\Delta SI = (SI_{stress} - SI_{rest} / SI_{rest})\ 100$$

Jahnke C et al: JACC CV Imaging 3 (2010) 375-84

BOLD Imaging: results

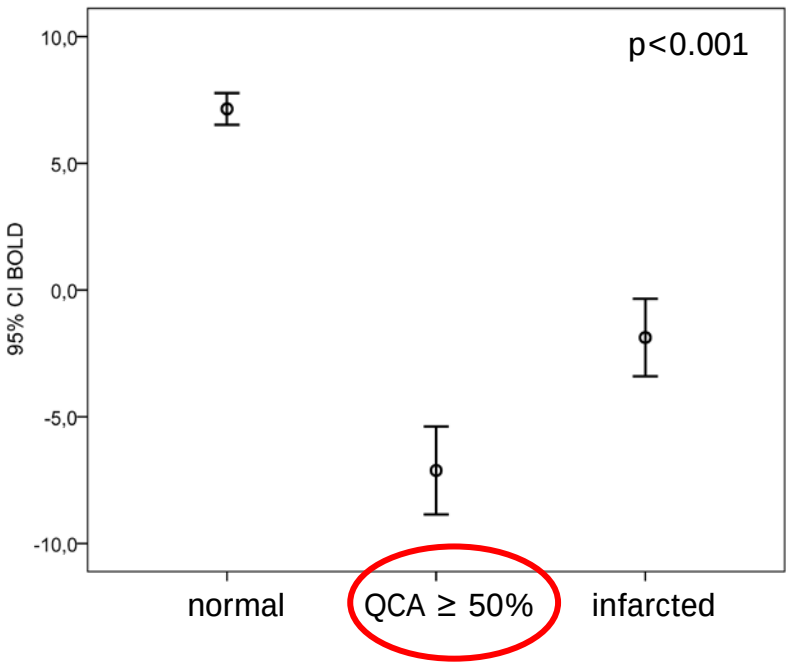

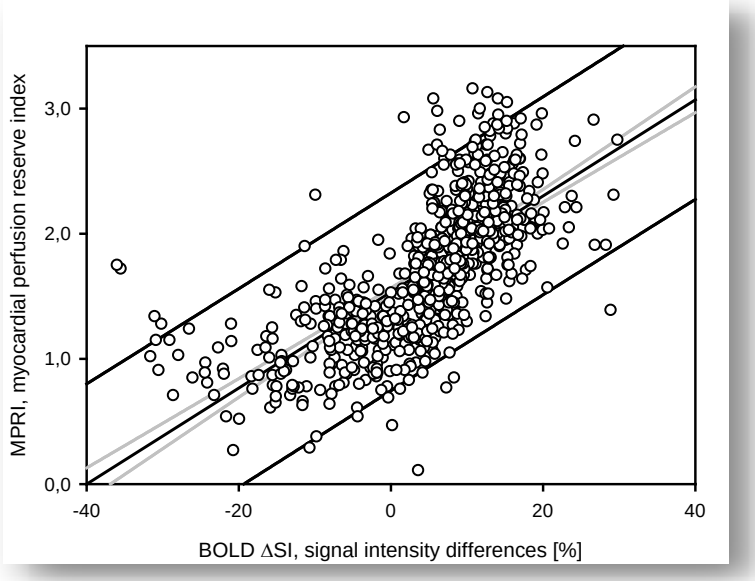

Cutoff of 2.7% for ΔSI : sensitivity = 85 %, specificity 80,5 %

Good correlation with the perfusion reserve index from first pass

QCA – quantitative coronary X-ray angiography

PHILIPS

Clinical value of 3.0 T

increased SNR at 3T

translates clinically into:

- enhanced patient throughput or
- improved analysis of morphological details with improved diagnostic accuracy
- improved functional analysis

and opens:

- new horizons in clinical MRI